



## Original Article

# Right internal mammary artery for the management of anomalous right coronary artery from the left sinus of Valsalva; a case report

Abdullah Alshehri, Khaled Alotaibi, Mortadha Alawami, Claudio Pragliola

Prince Sultan Cardiac Center, Saudi Arabia

### Abstract

**Background:** Anomalous origin of the right coronary artery from the left sinus of Valsalva (ARCA) is a rare anomaly. Surgery is recommended in symptomatic patients, while the optimal surgical approach is controversial.

**Case presentation:** We present a case of an ARCA in a 56-year-old male who was managed with coronary artery bypass grafting using the right internal mammary artery and ligation of the proximal right coronary artery. The patient remained asymptomatic after 1 year of follow-up.

**Conclusions:** ARCA can be managed using the right internal mammary artery with ligation of the proximal right coronary artery to prevent the competitive flow.

### KEYWORDS

Anomalous right coronary artery; Right internal mammary artery; Coronary artery anomaly

### Article History

Submitted: 17 Aug 2022

Revised: 27 Aug 2022

Accepted: 2 Sep 2022

Published: 1 Nov 2022

### Introduction

Anomalous right coronary artery [ARCA] from the left sinus of Valsalva is a rare congenital anomaly. The prevalence of coronary artery anomalies among adult patients who undergo coronary angiography was estimated to be 0.9% [1]. The prevalence of ARCA from the left sinus ranged from 0.02 to 0.2% [1] and it accounts for 8% of all coronary anomalies [1]. Many coronary artery anomalies are asymptomatic and discovered accidentally during coronary angiography. However, ARCA from the left sinus with an inter-arterial course is a relatively dangerous lesion. Patients with this anomaly could present with myocardial ischemia or sudden cardiac death [1]. The optimal surgical treatment of symptomatic patients with ARCA from the left sinus is controversial. Therefore, we present a case of ARCA from the left sinus of Valsalva who was managed with coronary artery bypass grafting [CABG] using the right internal mammary artery concomitant with ligation of the proximal right coronary artery.

### Case description

We present a case of a 56-year-old male patient who presented to our center with typical chest pain radiating to the left arm and related to physical activity. The pain started four years ago with increasing frequency, and the patient was completely asymptomatic before this. The patient underwent a stress ECG with negative results. The patient had no other symptoms, and the clinical examination was unremarkable. Echocardiography revealed normal cardiac functions and valves with no regional wall motion abnormalities. CT coronary angiography showed the anomalous origin of RCA from the left aortic sinus with an inter-arterial course between the aorta and right ventricular outflow tract. The anomalous artery had a separate slit-like orifice that originated with an acute angle. [Figure 1] Coronary angiography showed no other associated coronary lesions. Myocardial perfusion studies revealed reversible perfusion defects in the inferior wall.



The heart team decided to perform CABG. The patients underwent CABG with the right internal mammary artery to the right coronary artery concomitant with ligation of the proximal right coronary artery. Before ligation of the right coronary, the patient had poor flow detected with the flowmeter, and the flow improved significantly after ligation. [Supplementary file video] The patient had a smooth postoperative course and was discharged home after five days. The patient remained asymptomatic after 1 year of follow-up.

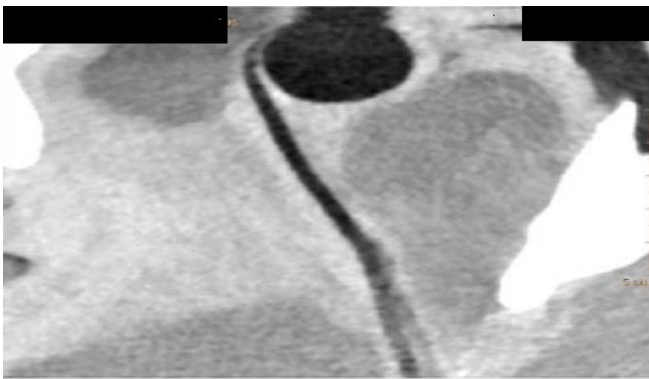


Figure 1: Anomalous origin of the right coronary artery from the left sinus of Valsalva with a slit-like opening

## Discussion

An anomalous right coronary artery from the left coronary sinus is a rare lesion. The inter-arterial course is a malignant course that could lead to sudden death [2]. The pattern and age of presentation of ARCA are variable. Our patient presented at 56 years old with a history of recurrent chest pain. The mechanism of angina is most probably due to compression of the artery between the aorta and pulmonary arteries. Still, it is not known why the patient remained asymptomatic for this long period before the presentation. The strenuous exercise was reported to cause sudden death in athletes with ARCA [3]. Therefore, the presentation of ARCA is more common in young adults contrary to our patient.

There are no clear guidelines for managing coronary artery anomalies; however, treatment is recommended in symptomatic patients with evidence of myocardial ischemia [4,5]. Treatment includes surgical, percutaneous interventions and medical management with or without strenuous exercise restriction [4]. Patients with asymptomatic ARCA and negative stress tests can

be managed conservatively [4]. American Heart Association/ American College of Cardiology recommended conservative management for patients with ARCA from left sinus with no symptoms and negative exercise testing [4]. Percutaneous coronary interventions were used to manage ARCA with good short-term relief of symptoms; however, long-term results are limited [4].

Patients with the intramural course can be managed with unroofing, and those with a separate orifice can benefit from right coronary artery reimplantation [6]. An Inter-arterial course is a malignant anomaly with a probability of sudden death. Therefore, some authors recommend early intervention in those patients [7]. Pulmonary artery translocation is another option to prevent coronary artery compression by moving the pulmonary artery anteriorly [8]. CABG remains a valid surgical option, while the ideal conduit is not established, and the graft's long-term patency is unknown. In our case, we used the right internal mammary artery and spared the internal mammary artery if future intervention is required. The use of the radial artery [7], left internal mammary, and gastroepiploic arteries [9] was previously reported. The long-term patency of the graft is questionable because of the competitive flow [10]; therefore, we ligated the proximal artery to prevent this complication.

## Conclusion

An anomalous right coronary artery from the left sinus of Valsalva can be the cause of angina in old age. The anomaly can be managed using the right internal mammary artery with ligation of the proximal right coronary artery to prevent the competitive flow. A long-term study to follow the graft patency is recommended.

**Supplementary file (Online):** Video showing the right internal mammary anastomosis to the proximal right coronary and the origin of the right coronary from the left sinus of Valsalva

**Conflict of interest:** Authors declare no conflict of interest.

## References

1. Yildiz A, Okcun B, Peker T, Arslan C, Olcay A, Bulent Vatan M. [Prevalence of coronary artery anomalies in 12,457 adult patients who underwent coronary angiography](#). Clin Cardiol. 2010; 33(12): E60-4.
2. Basso C, Maron BJ, Corrado D, Thiene G. [Clinical profile of congenital coronary artery anomalies with origin from the wrong aortic sinus leading to sudden death in young competitive athletes](#). J Am Coll Cardiol. 2000; 35 (6):1493–501.
3. Maron BJ, Haas TS, Ahluwalia A, Murphy CJ, Garberich RF. [Demographics and Epidemiology of Sudden Deaths in Young Competitive Athletes: From the United States National Registry](#). Am J Med. 2016; 129 (11): 1170–7.
4. Van Hare GF, Ackerman MJ, Evangelista J-AK, et al. [Eligibility and Disqualification Recommendations for Competitive Athletes With Cardiovascular Abnormalities: Task Force 4: Congenital Heart Disease: A Scientific Statement From the American Heart Association and American College of Cardiology](#). J Am Coll Cardiol. 2015; 66 (21): 2372–84.
5. Taylor AJ, Byers JP, Cheitlin MD, Virmani R. [Anomalous right or left coronary artery from the contralateral coronary sinus: “high-risk” abnormalities in the initial coronary artery course and heterogeneous clinical outcomes](#). Am Heart J. 1997 Apr;133[4]:428–35.
6. Brothers JA, Frommelt MA, Jaquiss RDB, Myerburg RJ, Fraser CDJ, Tweddell JS. [Expert consensus guidelines: Anomalous aortic origin of a coronary artery](#). J Thorac Cardiovasc Surg. 2017; 153 (6): 1440–57.
7. Bruls S, Durieux R, Gach O, Lancellotti P, Defraigne J-O. [Sudden Cardiac Death Revealed by an Anomalous Origin of the Right Coronary Artery From the Left Sinus of Valsalva](#). Ann Thorac Surg. 2020; 110 (4): e315–7.
8. Mainwaring RD, Reddy VM, Reinhartz O, et al. [Anomalous aortic origin of a coronary artery: medium-term results after surgical repair in 50 patients](#). Ann Thorac Surg. 2011; 92(2): 691–7.
9. Heo W, Min H-K, Kang DK, Jun HJ, Hwang Y-H, Lee HC. [Three different situations and approaches in the management for anomalous origin of the right coronary artery from the left coronary sinus: case report](#). J Cardiothorac Surg. 2014; 9: 21.
10. Gräni C, Buechel RR, Kaufmann PA, Kwong RY. [Multimodality Imaging in Individuals With Anomalous Coronary Arteries](#). JACC Cardiovasc Imaging. 2017;10 (4): 471–81.