



## Original Article

# Reconstruction of a Diffusely Diseased Left Anterior Descending Coronary Artery with Left Internal Thoracic Artery Patch: One-year Follow-up

Khaled Mohamed Abdelaal<sup>1</sup>, Ayman Mohammad Abdelghaffar<sup>1</sup>, Sharaf E.D. Mahmoud<sup>2</sup>, Mohamed Eid<sup>2</sup>, Abdelhady Ahmad Helmy<sup>3</sup>, Mohamed Abdel-Bary<sup>4</sup>

<sup>1</sup> Department of Cardiothoracic Surgery, Faculty of Medicine, Sohag University, Sohag, Egypt

<sup>2</sup> Department of Internal Medicine, Sohag Faculty of Medicine, Sohag University, Sohag, Egypt

<sup>3</sup> Department of Anesthesia and Intensive Care, Faculty of Medicine, Sohag University, Sohag, Egypt

<sup>4</sup> Department of Cardiothoracic Surgery, Qena Faculty of Medicine, South Valley University, Egypt

### Abstract

**Background:** Management of patients with extensive coronary artery disease (CAD) is challenging. This study presents the results of extensive reconstruction of the left anterior descending (LAD) coronary artery using the left internal thoracic artery (LITA) patch in patients with extensive LAD disease.

**Methods:** This study was conducted between January 2017 and April 2020 and included 86 patients. Males presented 88% (n=76), and the mean age was 57.8±7.31 years. Patients underwent long (2- 4 cm, n= 51) or extensive (≥4 cm, n= 35) segment reconstruction of the LAD using LITA graft. Associated comorbidities were diabetes mellitus (n= 68, 79%), hypertension (n=, 60, 69%), and chronic kidney disease (n= 5, 5.8%).

**Results:** The mean cardiopulmonary bypass and aortic cross-clamp times were 107 ±21.24 and 68±12.8 min, respectively. ICU stay ranged from 1 to 15 days and hospital stay from 6 to 30 days. Seven patients (8%) needed IABP, 3 (3.5%) had low cardiac output, 10 (11.5%) had pulmonary complications, 5 (5.8%) had mediastinitis, 7 (8%) had a stroke, and 5 (5.8%) had acute kidney injury. Mortality occurred in seven patients (8%), 4 (4.6%) had hospital mortality, and 3 (3.5%) had late mortality. During the 1-year follow-up, 7 (8%) patients had recurrent anginal pain. CT angiography showed patent LITA to LAD in 6 patients.

**Conclusion:** Extensive LITA patch reconstruction of the diffuse LAD disease could be a safe procedure with accepted early clinical outcomes.

### KEYWORDS

Left anterior descending coronary artery reconstruction; Extensive coronary artery disease; Endarterectomy; Left internal thoracic artery patch

### Article History

Submitted: 16 Nov 2021

Revised: 30 Nov 2021

Accepted: 6 Dec 2021

Published: 1 Mar 2022

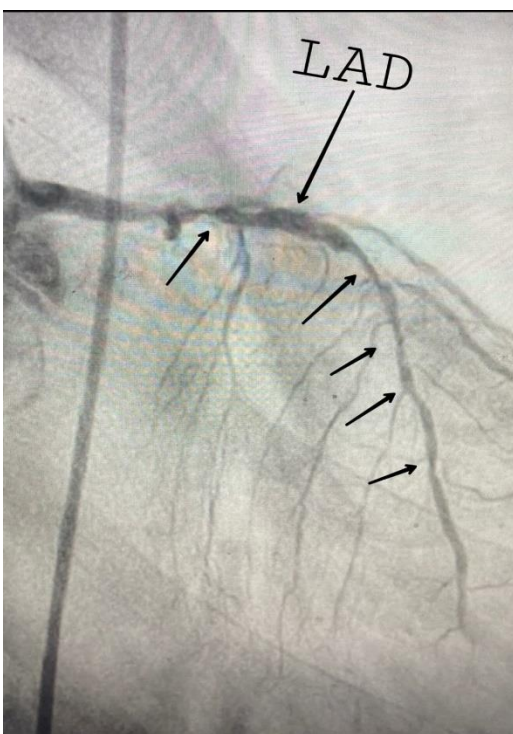
### Introduction

Coronary artery bypass grafting (CABG) increases life expectancy and improves the quality of life [1,2]. Its primary goal is to completely revascularize coronary arteries, particularly the left anterior descending (LAD) artery. The number of percutaneous coronary interventions (PCI) used

in treating patients with significant lesions is increasing [3]. Accordingly, individuals undergoing CABG are more likely to have complicated and extensive coronary artery disease (CAD) [4,5]. Nonetheless, until the revolution of reconstructive surgery, these patients were deemed not surgical candidates and treated medically [6]. One of the



CABG strategies for treating severe diffuse CAD is the reconstruction of the LAD. The major benefit of this approach is that it allows simultaneous revascularization of the myocardium fed by the side branches of the extensively diseased coronary arteries. The traditional grafting to the distal LAD alone would not provide this benefit since it would not perfuse the stenotic and more proximal segments [7-9]. Furthermore, there is a considerable risk of early graft occlusion [6]. Our study assessed the results of extensive LAD reconstruction by left internal thoracic artery (LITA) in patients with extensive LAD disease.



*Figure 1: Preoperative coronary angiography showing long segment extensively atherosclerotic disease affecting the left anterior descending coronary artery (Black arrows refer to stenosis sites)*

## Patients and Methods

### Study design

This research is an observational study conducted retrospectively from January 2017 to April 2020. It included 86 patients with diffuse extensive LAD disease who were not candidates for other conventional grafting techniques as double or sequential grafting. (Figure 1) The patients underwent long (2-4 cm, n= 51) or extensive ( $\geq 4$  cm, n= 35) segment reconstruction of the LAD using LITA graft. Patients with extensive LAD disease represented 13% of the total patients operated for isolated on-pump CABG in the same

period. Exclusion criteria were patients who had combined valvular procedures, re-do CABG and those who had LAD graft with a conduit other than LITA, and patients requiring endarterectomy in extensive CAD other than the LAD. The Local Ethical Committee approved the study, and the need for patients' consent was waived.

### Technique:

Conventional median sternotomy was done in all patients. A pedicled LITA and saphenous vein graft (SVG) were prepared. Aorto-common atrial cannulation and intermittent antegrade normothermic cardioplegia delivered every 20 min were used in all patients. The length of the LAD arteriotomy was estimated, and the LITA graft was fashioned correspondingly. Prolene (8-0 or 7-0) sutures were used for anastomosing LITA to the LAD. (Figure 2)

The suturing technique was designed to make the lateral plaques exterior to the anastomosis, leading to a smooth surface for blood flow at the anastomosis site, thus decreasing the risk of turbulence and thrombus formation [6, 7, 8]. An endarterectomy was performed when the LAD lumen was severely stenotic and obstructed.

Low-dose aspirin (75-100 mg) and clopidogrel (75 mg) were started on the postoperative day (POD) 1 in patients undergoing extensive reconstruction without endarterectomy. Low-dose aspirin and warfarin (target international normalized ratio is 2-2.5) were started on the POD 1 in patients undergoing endarterectomy. Intravenous heparin was continued until warfarin took effect. Clopidogrel and warfarin are discontinued six months after surgery.

Patients were followed-up in our department. Data were collected at 1, 6, and 12 months, including clinical examination, laboratory tests, electrocardiography, exercise stress testing, and echocardiography. Coronary artery CT angiography was done whenever there were new-onset symptoms, ECG changes, or regional wall motion abnormality in the follow-up echocardiography.

### Statistics analysis

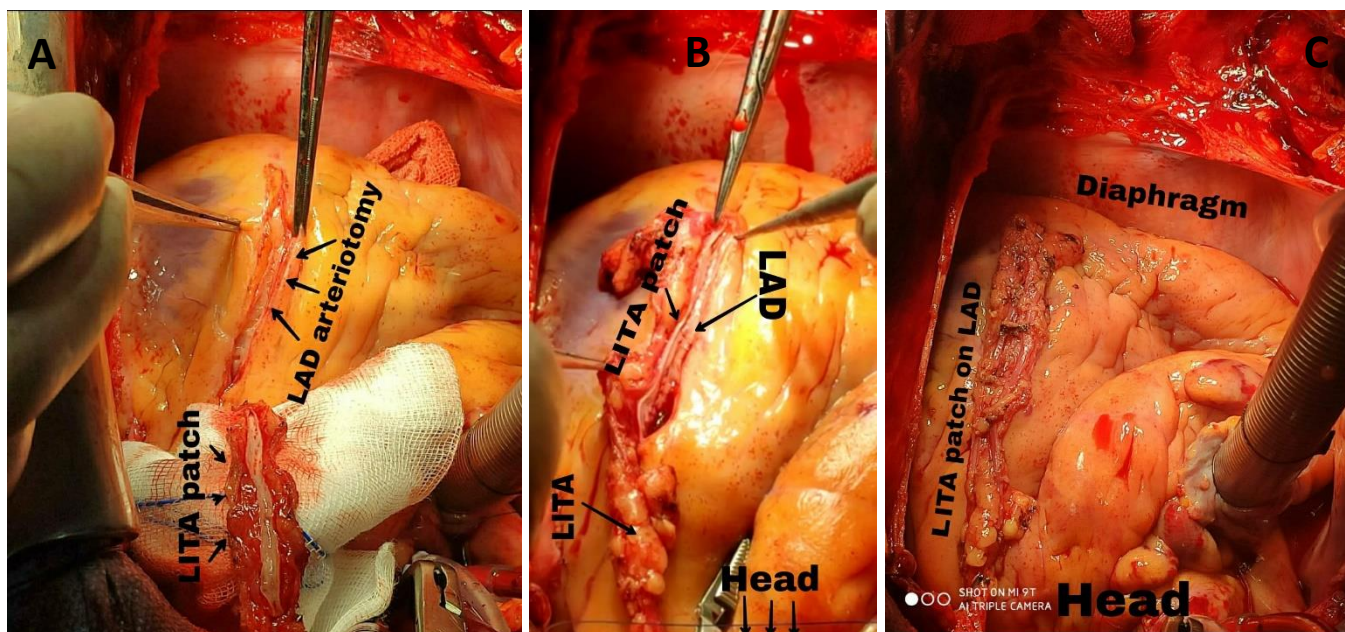


Figure 2: An intraoperative photos of extensive left anterior descending (LAD) coronary artery reconstruction with Left internal thoracic artery (LITA) patch; [A] preparation of the LITA patch and opening of the LAD before anastomosis; [B] a long LAD arteriotomy (>4 cm) was done, and one side of a long LITA patch was anastomosed to one side of LAD, [C] after finishing extensive LAD reconstruction with LITA patch

Continuous data were presented as mean and standard deviation (or minimum-maximum), and categorical data as frequencies and percentages. Descriptive analysis was performed using SPSS v23 (IBM Corp- Armonk- NY- USA).

## Results

### Preoperative data

This study included 86 diffuse extensive LAD disease patients. Males presented 88% of the total patients (n= 76), and the mean age was 57.8±7.31 years (range: 38-72 years). Coronary angiography (CA) showed that 21 (24%) patients had left main disease (LMD), and 70 (81%) of patients had triple vessel disease. Sixty-eight patients (79%) had diabetes mellitus, 60 (69%) had hypertension, and five (5.8%) had chronic kidney disease (CKD). Seventy-nine (91 %) patients were symptomatic in Canadian Cardiovascular Society class III and IV. Preoperative IABP was needed in five patients (5.8%) with severe LMD. (Table 1)

### Operative data:

The mean length of LAD reconstruction was 4.8 cm (range: 2.5- 9 cm). Endarterectomy was performed in 10 (11.6 %) patients. The mean cardiopulmonary bypass (CPB) and aortic cross-clamp times were 107 ±21.24 min (range 65-180

min) and 68±12.8 min (range 40-112 min), respectively.

Table 1: Preoperative patients characteristics

Variables	n=86
Male, n (%)	76 (88%)
Age (years), mean± SD	57.8 ±7.31
NYHA class (III, IV), n (%)	79 (91%)
Unstable angina, n (%)	19 (22%)
Previous myocardial infarction, n (%)	22 (25.5%)
Left main disease, n (%)	18 (21%)
Hypertension, n (%)	60 (69 %)
Diabetes mellitus, n (%)	68 (79 %)
Smoking, n (%)	65 (75%)
Hyperlipidemia, n (%)	40 (46.5%)
Chronic kidney disease, n (%)	5 (5.8 %)

NYHA: New York Heart Association

### Postoperative data:

Mean ICU stay was 3.7 days (range: 1- 15 days), mean hospital stay was 8.8 days (range 6–30 days). Seven patients (8%) needed IABP, 3 (3.5%) had low cardiac output, 10 (11.5%) had pulmonary complications, 5 (5.8%) had mediastinitis, 7 (8%) had a stroke, and 5 (5.8%) had acute kidney injury (3 patients treated conservatively and 2 need dialysis). Mortality occurred in seven patients (8%), 4 (4.6%) had hospital mortality (one



myocardial infarction and LCO on the 3rd postoperative day (POD), two strokes on the 7 and 10 PODs, and the 4th from pneumonia), and three during the follow up (two had congestive heart failure and one had a stroke). (Table 2)

Table 2: Intra and postoperative data

Variable	n= 86
<b>Aortic cross-clamp time (min), mean± SD</b>	68±12.8
<b>Cardiopulmonary Bypass time (min), mean± SD</b>	107±21.24
<b>Intensive care unit stay (days), mean (min- max)</b>	3.7 (1-15)
<b>Hospital stay (days), mean (min-max)</b>	8.8 (6–30)
<b>Intra-aortic balloon pump, n (%)</b>	7 (8 %)
<b>Low cardiac output, n (%)</b>	3 (3 %)
<b>Pulmonary complications, n (%)</b>	10 (11.5 %)
<b>Mediastinitis, n (%)</b>	5 (5.8 %)
<b>Exploration for bleeding, n (%)</b>	6 (7 %)
<b>Stroke, n (%)</b>	7 (8 %)
<b>Dialysis, n (%)</b>	2 (2 %)
<b>Pneumonia, n (%)</b>	3 (3 %)
<b>Mortality</b>	
Total, n (%)	7 (8%)
In hospital, n (%)	4 (4.6 %)
Late, n (%)	3 (3 %)

During one-year follow-up, seven (8%) patients had recurrent anginal pain, for whom CT coronary angiography was done. LITA to LAD long segment anastomosis was patent with good distal run-off in 6 patients. Two patients had a stroke (one died), and 5 (2 of them died) had congestive heart failure.

## Discussion

The rationale in CABG is to completely revascularize significant CAD stenosis, which substantially impacts the postoperative outcomes [10]. Incomplete revascularization of the LAD is an independent risk factor for unfavorable outcomes following CABG, either in the immediate postoperative period or afterward [11-13]. Extensive CAD can make surgical procedures more difficult and diminish graft patency in the long term [14]. Routine CABG in these cases may result in inadequate revascularization. A significant risk of early graft failure due to limited distal flow is

one of the challenges that cardiac surgeons encounter [15]. Despite the difficulties and high risk of CABG on patients with extensive CAD, they will have a worse prognosis if left untreated [12]. Revascularization cannot achieve the intended outcomes in patients with extensive LAD stenosis and is considered an independent risk factor for postoperative cardiovascular complications [16].

All the cases in our study had on-pump CABG. LAD reconstruction was done with a LITA patch in all cases because this long segment anastomosis necessitates CPB for a more secure anastomosis with adequate cardiac protection. Similarly, numerous studies used on-pump CABG for all their cases [17-20]. However, due to strong collaterals in patients with extensive CAD, the off-pump CABG can be successfully conducted by a surgeon with good surgical experience, as demonstrated in a study by Fukui and associates [7] and others [3,6,21].

There are two techniques for reconstructing the diffusely diseased LAD. The first option is to use a LITA patch to widen and reconstruct the LAD. Because of its established long-term patency and lower incidence of atherosclerosis, as stated in many studies, this is the most utilized technique and can offer more gratifying results [3,6,7,21,22]. The second option involves using an SVG patch to enlarge and reconstruct the LAD, followed by an end-to-side anastomosis between the LITA and the venous patch. In our study, 6 (86%) of the seven patients with a follow-up coronary CT angiography demonstrated a patent LITA to LAD long segment anastomosis with good distal run-off.

In most cases, the LITA patch was used to reconstruct the LAD lesion without endarterectomy. Endarterectomy was performed in 10 (11.6 %) of the patients in our study. It was done on a heavily calcified and atheromatous coronary artery with no anastomosis lumen. We avoided endarterectomy because intimal removal initiates the coagulation cascade in the early postoperative phase and causes myofibrointimal growth later, resulting in early thrombosis of septal and diagonal branches [23].

According to Fukui and colleagues, the LITA reconstruction patch resulted in a higher patency rate. According to the follow-up study, the arterial patency rate in the reconstruction group was 97.6%, compared to 89.7% in the endarterectomy group [8]. On the other hand, Kato and colleagues compared the long segment LAD reconstruction with and without endarterectomy. Except for a long surgery time in the endarterectomy cases, they found no significant differences in results. Both groups showed a non-significant difference in the overall survival rate and 10-year independence from severe adverse cardiac events [12].

Multiple drug-eluting stents have been implantation in many centers [26,27]. Nevertheless, there is a chance that the flow to the side branches will be affected. In addition, in-stent restenosis is frequent among these patients. On the other hand, surgical reconstruction has a little effect on blood flow to the side branches. Moreover, follow-up angiography revealed no restenosis in the reconstructed LAD. Therefore, it appears that the surgical procedure has certain benefits. Initially, it forms a new coronary wall made up of the LITA intima and disease-free coronary artery wall, which may aid in the repaired LAD's long-term patency. Also, the surgeon can see the ostia of the side branches up close, allowing for a safe anastomosis without occluding these vessels [7]. Graham and colleagues [25] found that patients with inoperable diffuse CAD had a 1-year survival rate of 60.8%. According to recent studies, patients who underwent CABG with endarterectomy had a 90% 5-year survival rate [21,22]. Our study showed that the thorough reconstruction of the diffusely diseased LAD with the LITA resulted in a 93% at one-year independence from death due to cardiac or cerebrovascular events.

### Study limitations

Some of the study's limitations are (1) the retrospective design, (2) the small number of patients, and the lack of long-term follow-up, (3) we did not compare extensive reconstruction to traditional CABG in patients with a diffusely diseased LAD and (4) In several cases, postoperative coronary angiography was not

performed. It is impossible to remark with precision on the patency of all grafts in diffuse CAD because CT coronary angiography was performed in just 7 (8%) of the 86 patients.

### Conclusion

Extensive LITA patch reconstruction of the diffuse LAD disease could be a safe procedure with accepted early clinical outcomes.

**Conflict of interest:** Authors declare no conflict of interest.

### References

1. Omar A, Mahmoud K. [Reconstruction of long left anterior descending coronary artery successive lesions with left internal mammary artery and saphenous vein graft angioplasty: Early encouraging results](#). Journal of the Egyptian Society of Cardio-Thoracic Surgery. 2016; 24:279-285.
2. Myers WO, Schaff HV, Gersh BJ, et al. [Improved survival of surgically treated patients with triple vessel coronary artery disease and severe angina pectoris. A report from the Coronary Artery Surgery Study \(CASS\) registry](#). J Thorac Cardiovasc Surg. 1989; 97:487-95.
3. Takanashi S, Fukui T, Miyamoto Y. [Coronary endarterectomy in the left anterior descending artery](#). J Cardiol. 2008; 52:261-8.
4. Filsoufi F, Rahmanian PB, Castillo JG, Chikwe J, Adams DH. [Excellent results of contemporary coronary artery bypass grafting with systematic application of modern perioperative strategies](#). Heart Surg Forum. 2007;10: E349-56.
5. Elbardissi AW, Balaguer JM, Byrne JG, Aranki SA. [Surgical therapy for complex coronary artery disease](#). Semin Thorac Cardiovasc Surg. 2009; 21:199-206.
6. Ramasubrahmanyam G, Panchanatheeswaran K, Varma Kalangi TK, Nagasaina Rao G. [Surgical management of diffusely diseased coronary arteries](#). Indian J Thorac Cardiovasc Surg. 2019; 35:453-460.
7. Fukui T, Tabata M, Taguri M, Manabe S, Morita S, Takanashi S. [Extensive Reconstruction of the Left Anterior Descending Coronary Artery With](#)

- an Internal Thoracic Artery Graft. *Ann Thorac Surg.* 2011; 91:445–51.
8. Fukui T, Takanashi S, Hosoda Y. Long segmental reconstruction of diffusely diseased left anterior descending coronary artery with left internal thoracic artery with or without endarterectomy. *Ann Thorac Surg.* 2005; 80:2098–105.
  9. Prabhu AD, Thazhkuni IE, Rajendran S, Thamaran RA, Vellachamy KA, Vettath MP. Mammary artery patch reconstruction of left anterior descending coronary artery. *Asian Cardiovasc Thorac Ann.* 2008; 16:313–7.
  10. Kleisli T, Cheng W, Jacobs MJ, et al. In the current era, complete revascularization improves survival after coronary artery bypass surgery. *J Thorac Cardiovasc Surg.* 2005; 129:1283–91.
  11. Cameron A, Davis KB, Green G, Schaff HV. Coronary bypass surgery with internal-thoracic-artery grafts—effects on survival over a 15-year period. *N Engl J Med.* 1996; 334:216–9.
  12. Brown RA, Shantsila E, Varma C, Lip GY. Epidemiology and pathogenesis of diffuse obstructive coronary artery disease: the role of arterial stiffness, shear stress, monocyte subsets and circulating microparticles. *Ann Med.* 2016; 48(6):444-55.
  13. Ngaage DL, Hashmi I, Griffin S, Cowen ME, Cale AR, Guvendik L. To graft or not to graft? Do coronary artery characteristics influence early outcomes of coronary artery bypass surgery? Analysis of coronary anastomoses of 5171 patients. *J Thorac Cardiovasc Surg.* 2010;140(1):66-72.
  14. Xiao C, Yang M, Liu G, Gao C. Reconstruction and revascularization for diffuse coronary artery disease by repair with a patch across the stenosis: report of 26 cases. *Military Med Res.* 2014;214(5):396-400.
  15. Barra JA, Bezon E, Mondine P, et al. Surgical angioplasty with exclusion of atheromatous plaques in case of diffuse disease of the left anterior descending artery: 2 years' follow-up. *Eur J Cardiothorac Surg.* 2000;17(5):509-14.
  16. Ostrom MP, Gopal A, Ahmadi N, et al. Mortality incidence and the severity of coronary atherosclerosis assessed by computed tomography angiography. *J Am Coll Cardiol.* 2008; 52 (16): 1335- 43.
  17. Fayad EA, Amr MA. Short-term outcomes of reconstruction of extensively diseased left anterior descending artery with or without endarterectomy: a propensity score analysis. *Cardiothorac Surg.* 2021; 29, 6.
  18. Li D, Guo P, Chen L, Wu Y, Wang G, Xiao C. Outcomes of Surgical Patch Angioplasty of The Coronary Artery for Diffuse Coronary Artery Disease. *Braz J Cardiovasc Surg.* 2020; 35 (5): 706-712.
  19. Elsayed MH, Hassanein WM, Keshk SA, Zidan M, Etman WG. Evaluation of different surgical modalities for coronary reconstruction of diffusely diseased left anterior descending artery. *Vessel Plus.* 2018; 2: 39.
  20. Kato Y, Shibata T, Takanashi S, Fukui T, Ito A, Shimizu Y. Results of long segmental reconstruction of left anterior descending artery using left internal thoracic artery. *Ann Thorac Surg.* 2012; 93(4):1195–1200.
  21. Ogus TN, Basaran M, Selimoglu O, et al. Long term results of the left anterior descending coronary artery reconstruction with left internal thoracic artery. *Ann Thorac Surg.* 2007; 83 (2): 496-501.
  22. Schwann TA, Zacharias A, Riordan CJ, Durham SJ, Shah AS, Habib RH. Survival and graft patency after coronary artery bypass grafting with coronary endarterectomy: role of arterial versus vein conduits. *Ann Thorac Surg* 2007; 84:25–31.
  23. Soyulu E, Harling L, Ashrafian H, Casula R, Kokotsakis J, Athanasiou T. Adjunct coronary endarterectomy increases myocardial infarction and early mortality after coronary artery bypass grafting: a meta-analysis. *Interact Cardiovasc Thorac Surg.* 2014; 19:462–73.
  24. Byrne JG, Karavas AN, Gudbjartson T, et al. Left anterior descending coronary endarterectomy: early and late results in 196 consecutive patients. *Ann Thorac Surg* 2004; 78: 867–73.
  25. Graham MH, Chambers RJ, Davies RF. Angiographic quantification of diffuse coronary artery disease. Reliability and prognostic value for bypass operations. *J Thorac Cardiovasc Surg.* 1999; 118: 618 –27.

26. Aoki J, Ong AT, Granillo GAR, et al. "Full metal jacket" (stented length 64 mm) using drug-eluting stents for de novo coronary artery lesions. *Am Heart J* 2005; 150: 994 –9.

27. Tsagalou E, Chieffo A, Iakovou I, et al. Multiple overlapping drug-eluting stents to treat diffuse disease of the left anterior descending coronary artery. *J Am Coll Cardiol*. 2005;45: 1570 –3.