



## Case Report

# Operating a recurrent synovial sarcoma of the sternoclavicular joint: a case presentation

Ahmed Mekkawy<sup>1</sup>, Mohamed Mostafa Elyounsi<sup>2</sup>

<sup>1</sup> Department of Cardiothoracic Surgery, Faculty of Medicine, Assuit University, Assuit, Egypt

<sup>2</sup> Department of Plastic Surgery, Faculty of Medicine, Assuit University, Assuit, Egypt

### Abstract

**Background:** Synovial sarcoma is one of the rarest soft tissue tumors with a high grade of malignancy. Primary synovial sarcoma of the chest wall is rare.

**Presentation of case:** A 65-year-old woman presented with history of left upper chest wall mass previously operated 9 months ago. The pathological report was a synovial sarcoma. Computed chest tomography was done and revealed a RT anterior infraclavicular mass with cystic solid lesions measuring 8.5 \*3.5\*4 cm.

**Conclusion:** The synovial sarcoma is aggressive malignancy and we think from the story of this case that early radical surgery plus systemic chemotherapy provides better outcome.

### KEYWORDS

Synovial sarcoma;  
Chest wall reconstruction;  
Chest wall tumor

### Article History

Submitted: 12 July 2021

Revised: 27 Aug 2021

Accepted: 3 Oct 2021

Published: 1 Jan 2022

### Introduction

Synovial sarcoma is one of the rarest soft tissue tumors with a high grade of malignancy developing mostly near large joints. The most common sites of origin are the thigh, knee, ankle, foot, and upper extremities. Primary synovial sarcoma of the chest wall is rare [1].

### Case presentation

A 65-year-old woman presented to the cardiothoracic surgery clinic with history of left upper chest wall mass previously operated (simple excision) 9 months ago by a general surgeon. The symptoms started as described by the patient by pain in the region of the sterno-clavicular joint, where the patient then noticed a gradually growing mass at the same site. She sought medical advice and operated the mass at a size of a small lemon. On examination there was a large mass orange like fixed to the chest wall at the upper medial part of the right chest with redness of the

skin over it and a scar of the previous surgery. The pathological examination of the previous surgery reports a synovial sarcoma. Computed chest tomography (CT) was done and revealed a right anterior infraclavicular complex mass lesion with cystic solid lesions measuring 8.5 \*3.5\*4 cm, with invasion to the pectoralis muscle and no intrathoracic extension, no invasion to subclavian vessels or bony structure of the chest wall, no mediastinal lymphadenopathy and clear both lungs' fields (Figure 1).

### Management

A whole-body survey was planned (brain, chest and abdomen CT), An ultrasonic Doppler was done on the right subclavian vessels to judge possibility of invasion. There was no availability of PET CT scan in Assiut university at this time. No evidence of distant metastasis was found. After consultation with plastic surgery department, we decided to do chest wall resection and



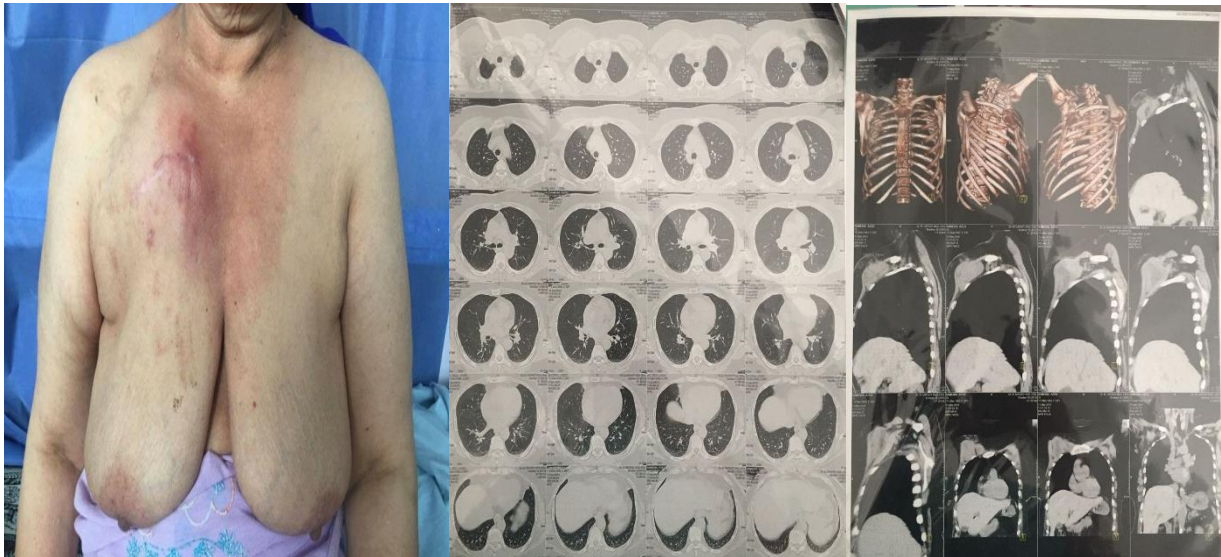

Figure 1: first picture from the left shows large fixed chest wall mass infraclavicular, previous surgical scar seen over it. CT shows extra thoracic subpectoral mass with close relation to the clavicle and no bone erosion

reconstruction with myocutaneous latissimus dorsi (LD) flap at the same sitting.

### Surgical technique

The thoracic stage started with an elliptical incision is done taking the whole red skin over the mass with 2 cm safety margin. resection of the mass, pectoralis muscles, the right half of the sternum opposite to the 1st and 2nd ribs, the sterno-clavicular joint, half of the clavicle, 1st and 2nd ribs was done, it was clear that the mass was arising from or near to the sterno-clavicular joint. Fixation of the remaining part of the clavicle to the first rib by a stainless-steel wire to improve the function of the right arm, then a bridging stainless-

steel wires between the sternum and 1st and 2nd ribs were taken to act as pillar to rest a polypropylene mesh over it. Careful dissection was done to separate the under surface of the sterno-clavicular joint from the subclavian vessels and right innominate vein. Ligation of the internal mammary vessels was done, also insertion of a right intercostal tube (Figure 2).

The reconstruction stage started preoperatively by marking with the patient in upright position. The skin paddle was located to lie along the natural resting tension lines and natural creases of the back, to maximize the skin paddle's volume and size.

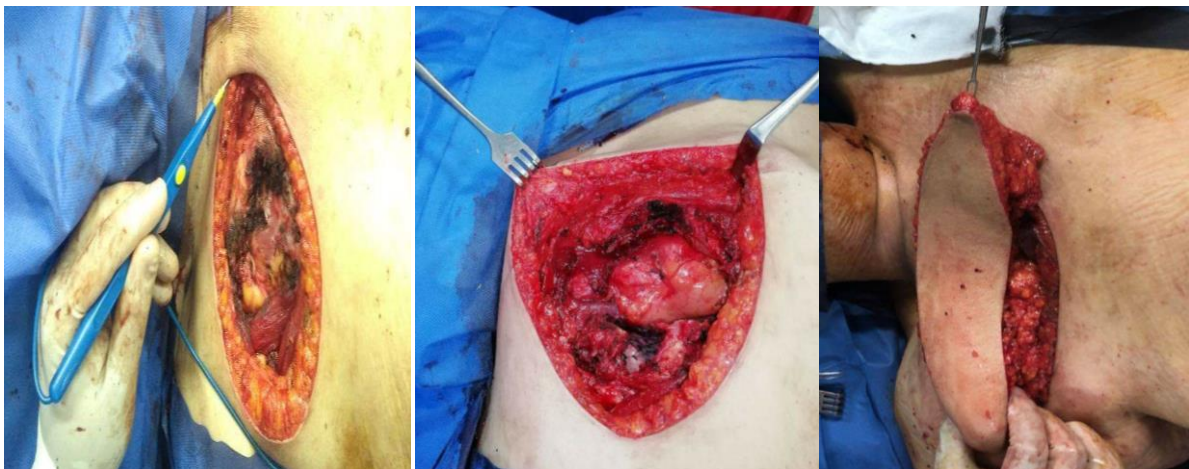


Figure 2: (the head to the left of the picture) first picture from the left shows resection of the mass and the pectoralis major muscle, pectoralis minor head appears laterally at the wound, the black areas (controlled by cautery) are the origin of the mass near to the sternoclavicular joint and the down surface of the clavicle. Second picture after resection shows the thymic fat in the middle of the picture, part of the superior vena cava, right and left innominate vein, part of the first and second rib after resection and the remaining left part of the manubrium sterni. Third picture shows the myocutaneous LD flap ready to cover the defect.

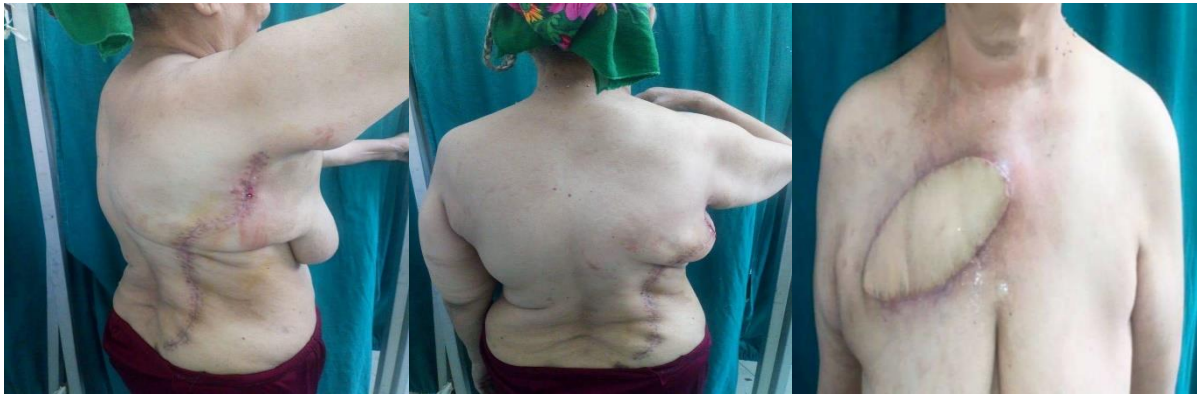

Figure 3: shows scar of the donar site, good function of the right arm and healed LD flap

The harvest of the LD flap and transfer were carried out while the patient in the lateral decubitus position. The initial incisions around the skin island are made with a knife and deepened with cutting diathermy until the distinct Scarpa's fascia was seen. The dissection of the flap can either be superficial or deep to the distinct fascia. In obese patients, dissecting through the fat above this layer leaving a thick layer of subcutaneous fat can be done. As the dissection continues superiorly in the direction of the axilla, from lateral to the outer border of the scapula, and just above its inferior angle the plane of dissection is deepened to the muscle surface and continued superiorly until the cut edge of the divided muscle is reached and the dissected axillary space is connected. The flap is rotated 180 pushed through the axilla to the breast (Figure 2). The donor area was closed in three layers using two suction drains to avoid any seroma or hematoma collection postoperatively.

The postoperative course was smooth clear from wound infection or other complication the patients was discharged home at the 7th day with good function of the Right arm (Figure 3).

After one month of surgery the patient was referred to the oncology clinic and planned to receive systemic chemotherapy. After two doses of chemotherapy the patient refused to continue the chemo therapy due to gastro-intestinal complications. The patient lost in follow up until she came with respiratory distress after 18 months and CT revealed multiple lung metastasis.

## Discussion

Synovial sarcomas are rare malignant tumors of unknown origin, most commonly affecting the lower extremities and frequently arises adjacent to joints or tendon sheaths. Synovial sarcoma is a misnomer, as it is not arising from the synovium, it only resembles synovial tissue at light microscopy. Since it appears to arise from multipotent stem cells that are capable of differentiating into mesenchymal or epithelial structures and lack synovial differentiation [1]. The Synovial sarcomas incidence approximately 5-14% of soft tissue sarcomas in different studies [2,3]. The synovial sarcoma may arise from head and neck, esophagus, retroperitoneum and also in the thorax; mediastinum, heart, lung, pleura or pericardium with lesser frequency [4, 5]. Synovial sarcomas rarely involve the chest wall. In literature there is less than 10 cases were reported [6-8]. The symptoms depend on the structures involved by compression or invasion from the tumor. Patients most commonly present with chest pain at first, chest wall swelling, cough, dyspnea and weight loss also common [9]. The computed tomography of synovial sarcoma of the chest wall is commonly characterized by a heterogeneously enhanced mass with well-defined margins, cortical bone destruction, tumor calcifications and tumor infiltration of the chest wall musculature. Mediastinal, hilar, diaphragmatic or axillary lymph nodes are rarely involved [10].

## Conclusion

The synovial sarcoma is a rare aggressive malignancy. The optimum line of treatment is like other chest wall sarcomas. So early radical surgery plus systemic chemotherapy provides the best outcome for the patients.



The lessons from sternoclavicular joint resection are careful dissection especially the under surface of the joint to avoid injury of the relating vessels. Fixation of the clavicle to the first rib or to the sternum by a bridging wire or plates if available is mandatory to preserve the weight bearing function of the right arm, the clavicle is a hard bone and it not easy to pass the stainless-steel wire needle through it, so you may need a driller to pierce it.

**Conflict of interest:** Authors declare no conflict of interest.

### References

1. Ruggiero A, Braham et al. Synovial sarcoma of the chest wall patho/GB/uk-synovialsarcoma. Orphanet Encyclopedia. 2004.
2. Spurrell EL, Fisher C, Thomas JM, Judson IR. [Prognostic factors in advanced synovial sarcoma: an analysis of 104 patients treated at the Royal Marsden Hospital](#). *Ann Oncol* 2005; 16: 437-44.
3. Marzano L, Failoni S, Gallazzi M, Garbagna P. [The role of diagnostic imaging in synovial sarcoma. Our experience](#). *Radiol Med*. 2004; 107: 533-40.
4. Bégueret H, Galateau-Salle F, Guillou L, et al. [Primary intrathoracic synovial sarcoma: a clinicopathologic study of 40 t\(X;18\)-positive cases from the French Sarcoma Group and the Mesopath Group](#). *Am J Surg Pathol*. 2005; 29: 339-46.
5. Miettinen M. Soft tissue tumors with epithelial differentiation. In: Miettinen M. eds. *Diagnostic soft tissue pathology*. Philadelphia, Pa: Churchill Livingstone, 2003;463-8.
6. Satoh H, Ohara G, Hizawa N. [Primary synovial sarcoma of the chest wall](#). *J Thorac Oncol*. 2007; 2: 1060.
7. Eisenberg RB, Horn RC. [Synovial sarcoma of the chest wall; report of a case](#). *Ann Surg* 1950; 131: 281-6.
8. Ouadnoui Y, Smahi M, Bouchikh M, et al. [A rare tumor of the chest wall: the synovial sarcoma](#). *Pan Afr Med J*. 2011; 9: 2.
9. Fatimi SH, Saleem T. [Giant synovial cell sarcoma of the thorax in a 46-year-old man: a case report](#). *Cases J*. 2009; 2: 9324.
10. Fujimoto K, Hashimoto S, Abe T, et al. [Synovial sarcoma arising from the chest wall: MR imaging findings](#). *Radiat Med*. 1997; 15: 411-4.