



## Original Article

# Early results of combined aortic arch debranching and thoracic endovascular re-pair

Abdullah Osama<sup>1</sup>, Omar Dawoud<sup>2</sup>

<sup>1</sup> Department of Cardiothoracic Surgery, Faculty of Medicine, Fayoum University, Fayoum, Egypt

<sup>2</sup> Department of Cardiothoracic Surgery, Faculty of Medicine, Cairo University, Giza, Egypt

### Abstract

**Background:** The hybrid technique for managing aortic arch diseases has been introduced recently into the surgical armamentarium. We aimed to evaluate the early post-operative outcomes after aortic arch debranching and endovascular repair (TEVAR) of aortic arch aneurysms or dissection.

**Methods:** Between March 2015 and September 2020, 17 patients underwent elective aortic arch debranching concomitant with TEVAR. Thirteen patients had aortic arch aneurysms, and four had chronic dissection. Study outcomes were early postoperative complications such as stroke, paraplegia, renal insufficiency, and 30-day mortality.

**Results:** The mean age of our patients was  $61.2 \pm 7.6$  years; 12 of them were males (70.6%). Five patients underwent total debranching (29.4%). All debranching procedures were followed with TEVAR. 30-day mortality, stroke, permanent paraplegia, and renal failure occurred in one patient (5.9%), while transient neurological deficit occurred in two patients (11.8%).

**Conclusion:** Hybrid management of aortic arch pathologies showed encouraging early results. The combination of surgical aortic arch debranching and TEVAR could be an option for managing aortic arch diseases. However, larger studies with longer follow up are recommended.

### KEYWORDS

TEVAR; Aortic arch; Debranching; Thoracic aorta

### Article History

Submitted: 4 Feb 2021

Revised: 21 Feb 2021

Accepted: 28 Feb 2021

Published: 1 July 2021

### Introduction

The technique of aortic arch debranching and endovascular aortic arch repair (TEVAR) has been widely adopted over the last few years. It showed promising early postoperative results, with low complications and mortality rates [1-4]. The conventional method to treat aortic arch diseases is the open surgical technique with deep hypothermic circulatory arrest combined with cerebral protective strategies [5,6].

The hybrid technique aims to limit operative time, avoid long bypass and total circulatory

arrest times, and simplify the overall procedure [7,8]. We aimed in our study to evaluate the early postoperative outcomes of aortic arch debranching and endovascular repair of aortic arch dissection or aneurysm.

### Patients and methods:

Our retrospective study included 17 patients requiring aortic arch intervention for aortic arch dissection or aneurysm between March 2015 and September 2020. We excluded patients who did not require arch vessel revascularization, patients with acute aortic dissection, and emergency

interventions. The Local Ethical Committee approved the study.

Patients' data required for this study were collected from our prospectively maintained database. Preoperative data included demographics, comorbidities, and aortic pathology (Table 1). All patients underwent computed tomographic (CT) angiography to determine the size and extent of aortic involvement. We collected data related to the operative techniques and postoperative complications.

The study outcomes were 30-day mortality, stroke, paraplegia, transient neurological deficit, and renal failure.

### Operative technique:

We tailored the operative technique according to the extent of arch pathology and planned landing zone. The debranching stage was performed in the operating room under general anesthesia.

In Zone 2, the carotid-subclavian bypass was performed through the neck and sub-clavicular incisions and using Dacron ring 8mm tube graft (Vascutek, Terumo, Japan). We exposed the left carotid artery through a neck incision along the left sternomastoid muscle's posterior border. The sub-clavicular incision was done two fingers below the middle third of the left clavicle.

In Zone 1, we performed innominate-carotid, and carotid-subclavian bypasses with Dacron grafts or debranching of the left subclavian and carotid arteries using a Dacron branched graft proximally anastomosed to the ascending aorta. In Zone 0, a total debranching of the three arch vessels was performed using a Dacron branched graft anastomosed proximally to the ascending aorta. The anastomosis was performed with a partial clamp technique and without cardiopulmonary bypass.

Six patients from the Zone 0 and 1 groups had the procedure performed through a mini-sternotomy (inverted T-shaped incision), and two patients required a full sternotomy.

Arch debranching was immediately followed by stent deployment under angiographic guidance in the Cath lab under general anesthesia. We used two types of stent-grafts in our study, Valiant Medtronic stent (Medtronic, Minneapolis, MN, USA) and Bolton Relay stent (Vascutek, Terumo, Japan). All stents were deployed through the common femoral artery with controlled hypotension during stent deployment. Trans-esophageal echocardiography (TEE) guidance was utilized in dissection cases to identify the true lumen. Regarding stent sizing, 20% oversizing was done in aneurysm cases with no oversizing in dissection cases.

### Statistical analysis

Statistical analysis was performed using Statistical Package for social sciences (SPSS) 20 software (IBM Corp, Armonk, NY, USA). Continuous variables were expressed as mean  $\pm$  standard deviation. Categorical variables were expressed as frequency and per-centages.

### Results:

#### Preoperative data:

Patient demographics and preoperative characteristics were described in Table 1. Thirteen patients had arch aneurysms; 10 of them extended into the descending aorta. Four patients had chronic type B aortic dissection; three had previous surgical re-placement of the ascending aorta.

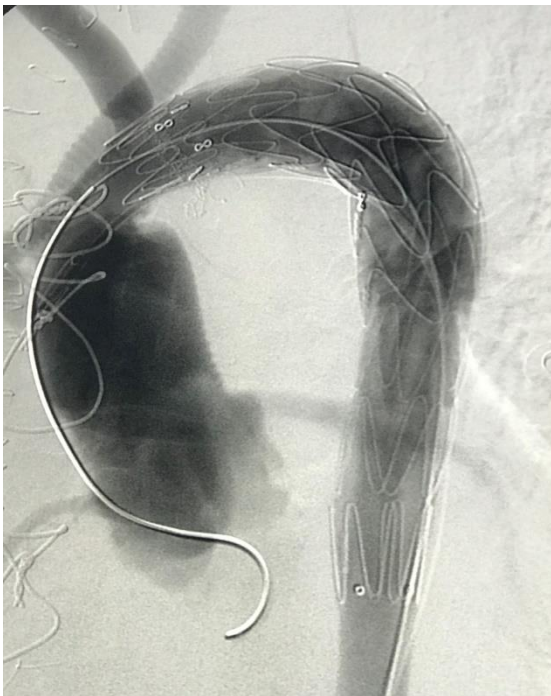
Table 1: Preoperative patient characteristics. Continuous data were presented as mean and SD, and categorical data as number and percentage.

Characteristic	(n= 17)
Age (Years)	61.2 $\pm$ 7.6
Males	12 (70.5%)
Chronic type B dissection	4 (23.5%)
Arch aneurysm	13 (76.5%)
Chronic renal insufficiency	1 (5.9%)
Hypertension	13 (76.4%)
Diabetes mellitus	3 (17.6%)

#### Operative data:

Five patients (29.4%) underwent total arch debranching, and the stent subsequently was landed in Zone 0. Three patients (17.6%) had debranching of the left common carotid and left

subclavian arteries, and the stent was anchored in Zone 1. Nine patients (52.9%) had carotid-subclavian bypass through a separate neck and infraclavicular incision with the stent deployed in Zone 2. Ten patients (58.8%) required coverage with a single endovascular stent, while the rest required the deployment of 2 endovascular stents. In all cases, TEVAR was performed immediately after completion of the de-branching procedure (Figure 1).



*Figure 1: Partial debranching and successful deployment of a Medtronic Valiant stent in zone 1. Tube graft is seen proximally anastomosed to ascending aorta, and no endoleak is visible after stent deployment.*

### Postoperative complications:

There was one postoperative mortality (5.9%). This patient had a stroke, and death occurred on postoperative-day 9. This patient had total debranching with an atherosclerotic arch aneurysm. Permanent paraplegia occurred in one patient with an extended area of stent coverage with two 200 mm stents deployed. Transient neurological deficit occurred in 2 cases; one suffered from mono-paresis immediately postoperatively but resolved spontaneously within hours. The other patient suffered from paraparesis, which resolved after cerebrospinal fluid (CSF) drainage and blood pressure adjustment. Renal failure requiring dialysis occurred in one case (5.9%), which had elevated

renal function preoperatively. Early morbidities and mortalities were summarized in Table 2.

*Table 2: Early postoperative complications. Data were presented as numbers and percentages. Data were presented as numbers and percentages.*

Postoperative complications	(n= 17)
<b>30-day mortality</b>	1 (5.9%)
<b>Stroke</b>	1 (5.9%)
<b>Permanent paraplegia</b>	1 (5.9%)
<b>Transient neurological deficit</b>	2 (11.8%)
<b>Renal failure</b>	1 (5.9%)

### Discussion

There is an increasingly growing interest in less invasive techniques utilized in managing aortic arch aneurysms and Stanford type B dissections involving the aortic arch. Combining surgical debranching with TEVAR offers a chance to avoid cardiopulmonary bypass, cerebral perfusion, and deep hypothermic circulatory arrest [9]. Whatever the technique, addressing aortic arch issues carries a significant risk of morbidity or mortality [10]. Regarding the open procedure for replacing the aortic arch surgically, large center studies, including a large number of patients, reported a mortality rate ranging from 0.9% to 9.3% [11]. The evolution of endovascular stenting and the aortic arch's debranching techniques provided competing results to the open surgical approaches. The availability of different techniques made it easier to approach each patient according to the anatomy, pathology, and comorbidities [12].

Our study showed an early mortality rate of 5.9%, which is similar to De Rango and coworkers (5.8%) [12] and lower than Bavaria and associated (11%) [13].

Neurological complications represent the achilles heel in the management of aortic arch pathologies. Manipulation in the aortic arch using guidewires, catheters, and high-profile stents may lead to embolization resulting in ischaemic stroke [14]. The stroke rate was 5.9% in this study compared to 11% in Bavaria and colleagues [13]. This may be explained by more than half of our patients (52.9%) required left subclavian artery debranching only and stent deployment in zone 2,

unlike Bavaria and coworkers, where all procedures were total debranching with stent deployment in zone 0, raising the risk of neurological affection. The proximal extent of the disease affecting the aortic arch is an important predictor for the patient's outcome. Extensive aortic atherosclerosis is a major risk factor for periprocedural stroke in endovascular aortic repair [15].

Extensive aortic and left subclavian artery coverage without revascularization may play a role in developing spinal cord ischemia and subsequent paraplegia [16]. Permanent paraplegia occurred in one patient (5.9%), and another one suffered temporary and reversible paraplegia after cerebrospinal fluid (CSF) drainage. This highlighted the importance of insertion of an intrathecal drain and CSF pressure monitoring in high-risk cases with extensive coverage or after the occurrence of spinal cord ischemia. Murashita and coworkers [9] showed a similar incidence of paraplegia (7.4%).

Renal failure in our study occurred in one patient. This patient had a preoperative renal impairment and suffered from renal failure post-intervention requiring renal replacement therapy. Bavaria and associates [13] reported a renal failure rate of 11%, which may be attributed to the higher percentage of patients suffering from renal impairment preoperatively (21%) and a higher mean age of their patients.

Selecting the appropriate technique to approach patients with aortic arch involvement should be carefully tailored for each patient according to the anatomy to achieve complete arch vessel revascularization.

Although addressing aortic arch diseases is associated with a considerable mortality rate, the short-term outcome of endovascular aortic arch repair with multiple debranching techniques is auspicious. It carries a low risk of complications and mortality.

## Conclusion

Hybrid management of aortic arch pathologies showed encouraging early results. The

combination of surgical aortic arch debranching and TEVAR could be an option for managing aortic arch diseases. However, larger studies with longer follow up are recommended.

**Conflict of interest:** Authors declare no conflict of interest.

## References

1. Koullias GJ, Wheatley III GH. [State-of-the-art of hybrid procedures for the aortic arch: a meta-analysis](#). *Ann Thorac Surg* 2010; 90: 689-97.
2. Cao P, De Rango P, Czerny M, et al. [Systematic review of clinical outcomes in hybrid procedures for aortic arch dissections and other arch diseases](#). *J Thorac Cardiovasc Surg* 2012; 144: 1286-300.
3. Zeeshan A, Woo EY, Bavaria JE. [Thoracic endovascular repair for acute complicated type B aortic dissection: superiority relative to conventional open surgical and medical therapy](#). *J Thorac Cardiovasc Surg*. 2010; 140: S109-15.
4. Antoniou GA, El Sakka K, Hamady M, Wolfe JH. [Hybrid treatment of complex aortic arch disease with supra-aortic debranching and endovascular stent-graft repair](#). *Eur J Vasc Endovasc Surg* 2010; 39: 683-90.
5. Harrington DK, Walker AS, Kaukuntla H. [Selective antegrade cerebral perfusion attenuates brain metabolic deficit in aortic arch surgery: a prospective randomized trial](#). *Circulation*. 2004; 110: II231-II236
6. Matalanis G, Hata M, Buxton BF. [A retrospective comparative study of deep hypo-thermic circulatory arrest, retrograde, and antegrade cerebral perfusion in aortic arch surgery](#). *Ann Thorac Cardiovasc Surg*. 2003; 9 (3): 174-179
7. Bavaria J, Milewski RK, Baker J, Moeller P, Szeto W, Pochettino A. [Classic hybrid evolving approach to distal arch aneurysms: toward the zone zero solution](#). *J Thorac Cardiovasc Surg*. 2010; 140: S77-80.
8. Weigang E, Parker J, Czerny M, et al. [Endovascular aortic arch repair after aortic arch debranching](#). *Ann Thorac Surg*. 2009; 87: 603-7.
9. Murashita T, Matsuda H, Domae K, et al. [Less invasive surgical treatment for aortic arch](#)

- aneurysms in high-risk patients: a comparative study of hybrid thoracic endovascular aortic repair and conventional total arch replacement. *J Thorac Cardiovasc Surg* 2012; 143: 1007-13
10. Patel HJ, Nguyen C, Diener AC, Passow MC, Salata D, Deeb GM. [Open arch re-construction in the endovascular era: analysis of 721 patients over 17 years.](#) *J Thorac Cardiovasc Surg*. 2011; 141: 1417-23
  11. Thomas M, Li Z, Cook DJ, Greason KL, Sundt TM. [Contemporary results of open aortic arch surgery.](#) *J Thorac Cardiovasc Surg*. 2012; 144: 838-44.
  12. De Rango P, Cao P, Ferrer C, et al. [Aortic arch debranching and thoracic endovascular repair.](#) *J Vasc Surg*. 2014; 59: 107–114
  13. Bavaria J, Vallabhajosyula P, Moeller P, Szeto W, Desai N, Pochettino A. [Hybrid approaches in the treatment of aortic arch aneurysms: postoperative and midterm outcomes.](#) *J. Thorac. Cardiovasc. Surg*. 2013; 145(3): S85–90.
  14. Bismuth J, Garami Z., Anaya-Ayala J, et al. [Transcranial Doppler findings during thoracic endovascular aortic repair.](#) *J Vasc Surg*. 2011; 54: 364-369
  15. Gutsche JT, Cheung AT, McGarvey ML, et al. [Risk factors for perioperative stroke after thoracic endovascular repair.](#) *Ann Thorac Surg*. 2007; 84: 1195-200.
  16. Greenberg R, Lu Q, Roselli E, et al. [Contemporary analysis of descending thoracic and thoracoabdominal aneurysm repair: a comparison of endovascular and open techniques.](#) *Circulation*. 2008; 118: 808-817