



Original Article

Partial versus Full Sternotomy for Aortic Valve Replacement

Islam Moheb Ibrahim, Ahmed Labib Dokhan, Mohammed Fawzy Eltaweel, Hesham Hassan Ahmed, Montaser Elsayy Abd Elaziz

Department of Cardiothoracic Surgery, Menoufia University, Menoufia, Egypt

Abstract

Background: Minimal invasive approaches are used more frequently for aortic valve replacement (AVR). This study aimed to compare the outcomes of both minimally invasive upper mini-sternotomy and full sternotomy for AVR.

Methods: 100 patients with isolated aortic valve disease were enrolled in this prospective observational study. We grouped the patients according to the technique, group A (n=40) underwent upper J-shaped mini-sternotomy, and group B (n=60) underwent full sternotomy. Study endpoints were operative times and pain score.

Results: The mean age of the patients was 46.4±10.1 years. There was no difference in preoperative data between both groups. There was a significant difference in aortic cross-clamp time (87.2± 8.6 vs. 59.2± 6.6 min in group A and B, respectively, p= 0.001), and total bypass time (115.1± 9.2 vs. 75.3± 4.3 min in group A and B, respectively, p= 0.001) between both groups. The total operative time was 341±11.7 and 196.1±18.4 min in groups A and B, respectively (p= 0.001). The ICU stay was 29.4±8.2 hours in group A and 41.2±13.3 hours in group B (p= 0.001). Patients who had mini-sternotomy had lower pain (p= 0.001) and better patient satisfaction score (p< 0.001).

Conclusion: J-shaped upper mini-sternotomy is a safe and effective strategy for aortic valve replacement. The procedure may be associated with decreased pain and comparable morbidity to the conventional approach.

KEYWORDS

Aortic valve replacement; Full sternotomy; Mini-sternotomy

Article History

Submitted: 14 June 2020

Revised: 15 June 2020

Accepted: 10 July 2020

Published: 1 Oct 2020

Introduction

Minimally invasive cardiac surgery enhances patients' recovery and decreases postoperative complications [1]. These techniques have proven safety and efficacy compared to the conventional approaches, in addition to the cosmetic effects [2]. Minimally invasive aortic valve replacement (AVR) showed better patients' satisfaction with early return to work and less postoperative pain [3].

The standard approach for AVR is through a median sternotomy. This approach is replaced by minimally invasive sternotomy incisions such as J,

C, L, and T mini-sternotomies [4]. The partial upper mini-sternotomy (MS) and the right anterior mini-thoracotomy (RT) are the most common minimally invasive approaches for cardiac surgery [5, 6]. The minimally invasive approaches are recently introduced to our institution. This study aimed to compare the outcome of both minimally invasive upper mini-sternotomy and full sternotomy for aortic valve surgery.

Patients and Methods:

Between October 2015 and March 2017, 100 patients with aortic valve disease were enrolled in



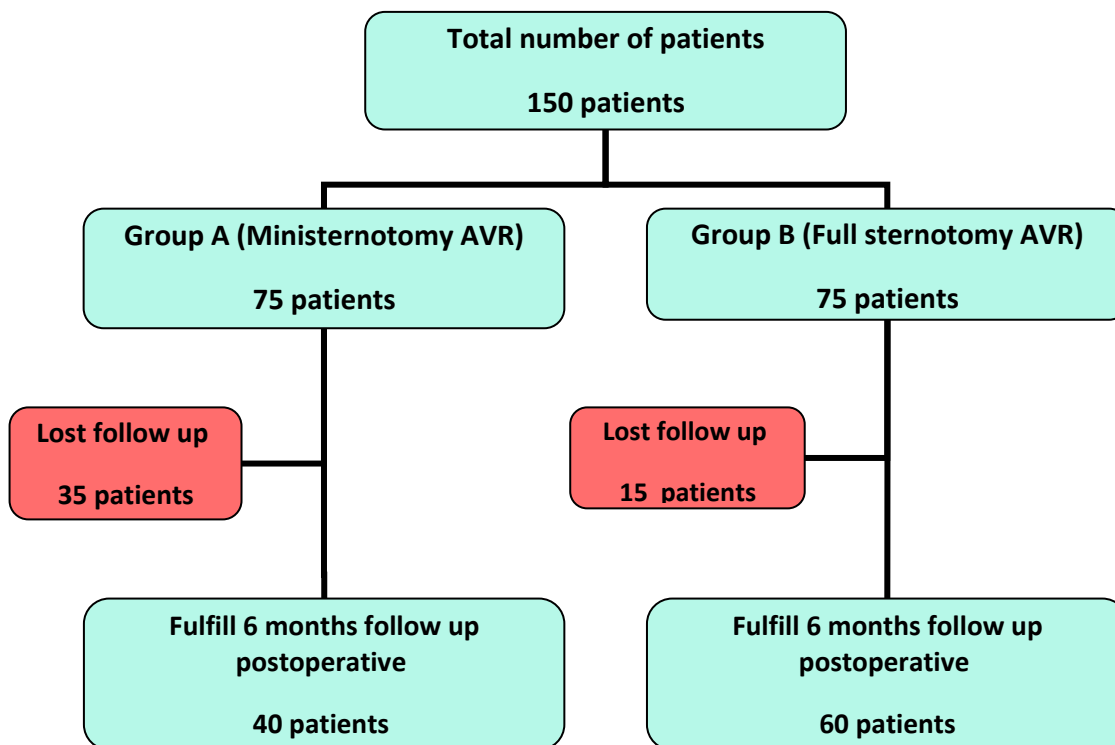


Figure 1: The study flow chart

a prospective study. We included patients who had primary isolated aortic valve replacement (AVR) and patients who had an emergency, re-operative AVR, and those who had concomitant procedures. Additionally, we excluded patients who were lost for follow-up. (Figure 1)

Forty patients in group A who had isolated aortic valve replacement through J-shaped upper mini-sternotomy were compared with 60 patients who had conventional aortic valve surgery (Group B). The decision to choose either mini-sternotomy or full sternotomy was based on surgeons' choice.

Our Institutional Ethical Committee approved the study protocol, and informed written consent was obtained from all patients before enrollment.

Operative technique:

All patients were subjected to the same anesthesia protocol. Transesophageal echocardiography "TEE" probe was inserted in all patients. Patients in group A had a J-shaped incision to the right-side with the transverse limb at the level of the 4th intercostal space. This technique was done to spare the right internal mammary artery. A full median sternotomy was

used in patients in group B. All patients had aortocaval cannulation and a right superior pulmonary vein vent.

Myocardial protection was achieved via antegrade warm blood cardioplegia. After we performed AVR in the usual way, the sternum was closed using sternal wires. However, in Group (A), we added one oblique wire placed between the lower intact segment of the sternum and the angular segment of the incision. We collected the total operative time, cardiopulmonary bypass, and aortic cross-clamp times.

The postoperative data were collected, including the duration of ICU and hospital stay, the amount of blood loss, pain and patient satisfaction scores. We assessed the patient satisfaction with a 5-point score in which 1 means very satisfied, and 5 means very unsatisfied. We used a numerical rating scale ranging from 0 to 10 to assess pain. Echocardiographic evaluation was performed postoperatively.

Statistical analysis:

The statistical analysis was performed using SPSS version 26 (IBM Corp, Chicago, IL, USA). The

Table 1: Demographic & Preoperative Data. Continuous data are presented as mean and standard deviation, and categorical variables are number and percent.

	Group A (n= 40)	Group B (n= 60)	P	
Female	24 (60%)	26(43.3%)	0.25	
Age (years)	45.1± 8.5	46.8 ± 10.6	0.66	
BMI (Kg/m2)	27.7 ± 2.5	26.7 ± 1.7	0.18	
Co-morbidities	Diabetes Mellitus	22 (55%)	24 (40%)	0.29
	Hypertension	17 (42.5%)	38 (63.3%)	0.9
	Dyslipidemia	10 (25%)	4 (6.7%)	0.06
Symptoms				
NYHA	Class II	14 (35%)	20 (33.3%)	0.99
	Class III	22 (55%)	34 (56.7%)	
	Class VI	4 (10%)	6 (10%)	
Chest pain	28 (70%)	34 (56.7%)	0.34	
Palpitation	8 (20%)	10 (16.7%)	0.76	

BMI: Body Mass Index, NYHA: New York Heart Association Classification.

quantitative values were presented as mean ± standard deviation and compared with student t-test or Mann-Whitney test. The qualitative values were compared using the Chi-square test and Fisher exact test when appropriate and presented as number and percent. A p-value of <0.05 was considered significant.

Results

Preoperative data:

Forty patients in group A had AVR via upper mini-sternotomy, and sixty patients in group B had full sternotomy AVR. There was no statistically significant difference between both groups regarding sex, age, height, weight, and BMI. No patients had hepatic or coronary artery disease. Preoperative variables are presented in Table 1.

Operative data:

There was a significant difference in aortic cross-clamp time (87.2± 8.6 vs. 59.2± 6.6 min in group A and B, respectively), and total bypass time

(115.1± 9.2 vs. 75.3± 4.3 min in group A and B, respectively) between both groups. The total operative time was 341±11.7 and 196.1±18.4 min in groups A and B, respectively. (Table 2)

Postoperative data:

The ICU stay was 29.4±8.2 hours in group A and 41.2±13.3 hours in group B. No patient had wound infections or exploration for bleeding in both groups. (Table 3) Patients who had mini-sternotomy had lower pain (p= 0.001) and better patient satisfaction (p< 0.001). (Table 3 and 4)

Discussion

Minimally invasive cardiac surgery has several advantages, including shorter hospital stay and better cosmetic results [7]. Aortic valve replacement is commonly performed in young patients because of the high prevalence of rheumatic fever [8]. Although median sternotomy is the classic approach for AVR, minimally invasive

Table 2: Operative data. Continuous data are presented as a mean and standard deviation.

	Group A (n= 40)	Group B (n= 60)	P
Cross clamp time (min)	87.2± 8.6	59.2± 6.6	0.001
Total bypass time (min)	115.1± 9.2	75.3± 4.3	0.001
Operative time (min)	341±11.7	196.1±18.4	0.001
Volume of blood transfusion (ml)	860±164.6	930±165.3	0.35

Table 3: Postoperative data. Continuous data are presented as mean and standard deviation, and categorical variables are number and percent.

	Group A (n= 40)	Group B (n= 60)	P	
Mechanical ventilation (hours)	5.3±1.7	5.4±1.5	0.8	
Circulatory inotropes	34 (85%)	58 (96.7%)	0.3	
Blood loss in first 24 hr (ml)	360±51.6	395±89.6	0.29	
ICU stay (hours)	29.4±8.2	41.2±13.3	0.001	
Arrhythmia	4 (10%)	8 (13.4%)	0.72	
Pain score	1st day	4.1 ± 0.7	6.2 ± 1.0	0.001
	2nd day	1.4 ± 0.5	4.4 ± 0.7	0.001
	3rd day	0.9 ± 0.4	4.0 ± 0.8	0.001
	4th day to discharge	0.7 ± 0.5	3.2 ± 0.6	0.001
Length of the wound (cm)	7.9±0.5	26.6±1.6	0.001	

ICU: Intensive Care Unit

approaches have recently developed to replace sternotomy [9].

A review of the outcomes of patients who had a partial sternotomy approach proved that the procedure is safe and effective for AVR [10]. Mikus and colleagues documented that re-operative AVR through an upper 'J' sternotomy had similar morbidity and mortality rate compared to the conventional approach [11].

Reser and colleagues found that J-shaped upper mini-sternotomy patients had less postoperative complications such as bleeding, wound infection, pain, faster recovery, and favorable long-term outcomes even in elderly and redo patients when compared with conventional sternotomy [12]. One of the most important advantages of partial sternotomy is the increased stability of the thoracic cage, which enhances early patients' mobility [13].

The preoperative characteristics were comparable between both groups and were within the published ranges [3, 4, 14]. Operative time, cardiopulmonary and cross-clamp times

were shorter in patients who had a full sternotomy. These findings were in agreement with that of Ferreira and colleagues and Foghsgaard and coworkers [8, 15]. The longer times can be explained by the narrow operative field and the difficulties encountered to insert pacemaker wires. However, hemostasis in minimally invasive approaches is shorter, which represents another advantage of this approach. Our study showed a non-significant difference in postoperative drainage between both groups. Brown and colleagues reported that mini-sternotomy had lower rates of bleeding in the first postoperative day in comparison to full sternotomy [16]. Gilmanov and coworkers and Shehada and colleagues showed that there was less blood transfusion needed for upper mini-sternotomy [17, 18]. On the other hand, the smaller incision used in mini-sternotomy hampers better exposure compared to the full sternotomy. In our study, we recorded lower rates of bleeding in mini-sternotomy than full sternotomy. However, according to the literature, the improvement of surgical skills can contribute to reducing bleeding with mini-sternotomy [19, 20]. Furthermore, there are less postoperative.

Table 4: Patients satisfaction score

Group	Scale Score (%)				
	1	2	3	4	5
Group A (n= 40)	28 (70%)	12 (30%)	0	0	0
Group B (n= 60)	0 (0%)	12 (20%)	30 (50%)	18 (30%)	0

complications with upper mini-sternotomy in our study that include wound infection, and the ICU stay. Our findings are similar to other studies as Mikus and colleagues that showed significantly less mechanical ventilation time in mini-sternotomy, which is similar to other studies [11, 16 – 18].

ICU stay was significantly less in the mini-sternotomy group, similar to what was previously reported [14]. But this was different from the results reported by Ferreira and colleagues. They reported an average length of stay in the ICU 93.6 ± 6 hours for the sternotomy approach and 81.6 ± 20 days for the mini-sternotomy approach with no significant differences [8].

We had significantly lower postoperative pain scores in patients with mini-sternotomy during the first postoperative days ($P=0.001$). We reported a lower mean duration of hospital stay in the mini-sternotomy group, but without significant difference ($P=0.11$). Ferreira and colleagues supported these findings. In their study, the sternotomy group showed that the mean hospital stay duration was 11 ± 9.0 days, and in the mini-sternotomy group was 7.1 ± 2.0 days, with no significant difference ($P=0.46$) [8].

Patients who had better satisfaction scores at the time of hospital discharge had an early return to physical activity. Recently, Fudulu and colleagues reported that minimally invasive aortic valve surgery was safe and effective with a comparable mortality and mid-term survival to conventional aortic valve surgery. Minimally invasive-AVR resulted in improved ventilatory function and renal function, reduced wound infection and shorter hospital stay [13].

Conclusion

J-shaped upper mini-sternotomy is a safe and effective strategy for aortic valve replacement. The procedure may be associated with decreased pain and comparable morbidity to the conventional approach.

Conflict of interest: Authors declare no conflict of interest.

References

1. Brinkman WT, Hoffman W, Dewey TM et al. [Aortic Valve Replacement Surgery: Comparison of Outcomes in Matched Sternotomy and PORT ACCESS Groups](#). *Ann Thorac Surg*. 2010; 90 (1): 131–135.
2. Cao C, Gupta S, Chandrakumar D et al. [A meta-analysis of minimally invasive versus conventional mitral valve repair for patients with degenerative mitral disease](#). *Ann Cardiothorac Surg*. 2013; 2(6): 693–703.
3. Kaczmarczyk M, Szałański P, Zembala M et al. [Minimally invasive aortic valve replacement – pros and cons of keyhole aortic surgery](#). *Kardiochir Torakochirurgia Pol*. 2015; 12(2): 103-110.
4. Federico A, Paredes A, Sergio J et al. [Minimally Invasive Aortic Valve Surgery. A Safe and Useful Technique Beyond the Cosmetic Benefits](#). *Rev Esp Cardiol*. 2013; 66 (9): 695-699.
5. Glauber M, Ferrarini M, Miceli A. [Minimally invasive aortic valve surgery: state of the art and future directions](#). *Ann Cardiothorac Surg*. 2015; 4(1): 26-32.
6. Soppa G, Yates M, Viviano A et al. [Aortic valve replacement through J-shaped partial upper sternotomy](#). *J Thorac Dis*. 2013; 5(Suppl 6): S662–S668.
7. Iribarne A, Easterwood R, Chan EYH et al. [The golden age of minimally invasive cardiothoracic surgery: current and future perspectives](#). *Future Cardiol*. 2011; 7(3): 333 - 346.
8. Ferreira RTR, Silva RR, Marchi E. [Aortic Valve Replacement: Treatment by Sternotomy versus Minimally Invasive Approach](#). *Braz J Cardiovasc Surg*. 2016; 31(6): 422 - 427.
9. Fared S, Abou Senna W, Sewielam M, Fouad A, Sabry A, Bassiony A. [Early outcome of minimally invasive mitral valve surgery](#). *Journal of the Egyptian Society of Cardio-Thoracic Surgery*. 2016; 24 (2): 173-180.
10. Raja SG, Benedetto U, Amrani M. [Aortic valve replacement through J-shaped partial upper sternotomy](#). *J Thorac Dis*. 2013; 5(Suppl 6): S662–S668.
11. Mikus E, Calvi S, Tripodi A, Lamarra M, Del Giglio M. [Upper 'J' ministernotomy versus full](#)

- sternotomy: an easier approach for aortic valve reoperation. *J Heart Valve Dis.* 2013; 22 (3): 295-300.
12. Reser D, Holubec T, Scherman J, Yilmaz M, Guidotti A, Maisano F. [Upper ministernotomy](#). *Multimed Man Cardiothorac Surg.* 2015.
 13. Fudulu D, Lewis H, Benedetto U, Caputo M, Angelini G, Vohra HA. [Minimally invasive aortic valve replacement in high risk patient groups](#). *JTD.* 2017; 9 (6): 1672.
 14. Amr MA. [Evaluation of feasibility and outcome of isolated aortic valve replacement surgery through J-shaped upper ministernotomy: A comparative study versus full sternotomy](#). *Journal of the Egyptian Society of Cardio-Thoracic Surgery.* 2016; 24 (2): 123-130.
 15. Foghsgaard S, Schmidt TA, Kjaergard HK. [Minimally Invasive Aortic Valve Replacement Late Conversion to Full Sternotomy Doubles Operative Time](#). *Tex Heart Inst J.* 2009; 36(4): 293-297.
 16. Brown JM, O'Brien SM, Wu C, Sikora JAH, Griffith BP, Gammie JS. [Isolated aortic valve replacement in North America comprising 108,687 patients in 10 years: changes in risks, valve types, and outcomes in the Society of Thoracic Surgeons National Database](#). *J Thorac Cardiovasc Surg.* 2009; 137 (1): 82-90.
 17. Gilmanov D, Miceli A, Ferrarini M, et al. [Aortic valve replacement through right anterior minithoracotomy: can sutureless technology improve clinical outcomes?](#). *Ann Thorac Surg.* 2014; 98: 1585-1592.
 18. Shehada SE , Öztürk O, Wottke M , Lange R. [Propensity Score Analysis of Outcomes Following Minimal Access Versus Conventional Aortic Valve Replacement](#). *Eur J Cardiothorac Surg.* 2015; 49 (2): 464-470.
 19. Johnston WF, Ailawadi G. [Surgical management of minimally invasive aortic valve operations](#). *Semin Cardiothorac Vasc Anesth.* 2012; 16 (1): 41-51.
 20. Plass A, Scheffel H, Alkadhi H, et al. [Aortic valve replacement through a minimally invasive approach: preoperative planning, surgical technique, and outcome](#). *Ann Thorac Surg.* 2009; 88(6): 1851-1856.