



Original Article

Skeletonized versus pedicled left internal mammary artery harvesting and risk of sternal wound infection after coronary artery bypass surgery

Ahmed Mohamed Farghaly¹, Mohamed Alaa Nady², Ahmed Elminshawy³

¹ Department of Cardiothoracic Surgery, Faculty of Medicine, Minia University, Minia, Egypt

² Department of Cardiothoracic Surgery, Faculty of Medicine, Assiut University, Assiut, Egypt

³ Department of Cardiothoracic Surgery, Graduate Studies and Research, Faculty of Medicine, Assiut University, Assiut, Egypt

Abstract

Background: The left internal mammary artery (LIMA) is the gold standard conduit for coronary artery bypass grafting (CABG). There are two harvesting methods, either pedicled or skeletonized. The choice of any technique must consider its complication profile, especially sternal wound infections (SWI). This study aims to evaluate and compare the occurrence of SWI after pedicled and skeletonized LIMA harvesting techniques for CABG.

Methods: This prospective observational study included 300 patients who had CABG between 2016 and 2019. We included patients who had pedicled LIMA (n=200) in group 1 and who had skeletonized LIMA (n=100) in group 2. All patients completed a follow-up period of 3 months after CABG. The evaluation during follow-up included: sternal instability, signs of wound infection, temperature, the microbiological study of wound discharge, and chest computed tomography scan.

Results: There was no significant differences in age ($p = 0.20$), male to female ratio ($p = 0.43$), body mass index ($p = 0.12$), NYHA I/II ($p = 0.50$), diabetes mellitus ($p = 0.28$), ejection fraction ($p = 0.14$), and EuroSCORE II ($p = 0.09$) between groups. No significant difference in cardiopulmonary bypass time ($p = 0.24$), and cross-clamp time ($p = 0.19$) between groups. There was a significant increase in the total operating time in skeletonized LIMA group (212.77 ± 75.25 min vs. 190.78 ± 55 minutes, $p = 0.004$). Skeletonized LIMA was significantly associated with lower incidence of SWI than that with pedicled LIMA (4% vs 15.5%, $p = 0.003$), and non-significantly lower incidence of deep SWI (1% vs 4.5%, $p = 0.11$). The risk factors for SWI in patients who had pedicled IMA were obesity (OR: 13.06, 95%CI: 3.98-42.89), diabetes mellitus (OR: 10.51, 95%CI: 2.35-46.84), and excessive diathermy (OR: 12.62, 95%CI: 3.93-40.54).

Conclusion: Obesity, diabetes, and the use of excessive diathermy for hemostasis may increase the risk of sternal wound infection with pedicled LIMA harvest compared to skeletonized LIMA in patients undergoing CABG.

KEYWORDS

Coronary artery bypass grafting; Skeletonized; Pedicled; LIMA; Sternotomy

Article History

Submitted: 15 Apr 2020

Revised: 25 Apr 2020

Accepted: 29 May 2020

Published: 1 Oct 2020



Introduction

Coronary artery bypass grafting (CABG) surgery is a widely accepted option for surgical treatment of coronary artery diseases (CAD). Although various conduits have been utilized in CABG, the left internal mammary artery (LIMA) has become the gold standard conduit for grafting the left anterior descending (LAD) artery [1]. LIMA has a high patency rate at ten years, with little or no atherosclerotic changes [2].

The influence of LIMA in clinical practice is diverse, and the variation is attributed to the different harvesting techniques. Generally, two harvesting methods are well established: pedicled and skeletonized methods. The pedicled technique dissects the artery far from the chest wall with its accompanying veins, fascia, fat, and lymphatics. In contrast, skeletonization solely dissects the LIMA away from the chest wall without the accompanying structures [3].

The preferred harvesting technique has been periodically debated, as each technique is associated with its advantages and disadvantages. In comparison to the pedicled technique, skeletonization provides longer conduit, better free flow, and less pain [4]. On the contrary, skeletonization is technically more demanding, and theoretically, harvesting the vessel without the surrounding fat may reduce its long-term resistance because it is subjected to more direct contact with the surrounding structures and more pronounced surgical trauma [5].

The selection of the harvesting technique must incorporate consideration of its complication profile with a deep concern to the possibility of sternal wound infections (SWI). It has been suggested that the pedicled technique is associated with increased SWI owing to the reduced sternal vascularization [6]. On the other hand, skeletonization presents better preservation of sternal micro-circulation that might be a protective factor against SWI [5]. The study aimed to compare the occurrence of SWI following pedicled versus skeletonized LIMA harvesting in patients undergoing CABG and to evaluate the risk factors for SWI.

Patients and Methods:

Design and patients

We conducted this prospective observational study between July 2016 and June 2019. We included adult patients of both genders who underwent isolated, elective, on-pump CABG via full median sternotomy. The study excluded patients with concomitant cardiac surgery, previous cardiac surgery, emergency surgery and those who had total arterial revascularization, concomitant carotid artery surgery, minimally invasive direct CABG (MIDCAB), and off-pump CABG. Patients with hepatic/renal failure, overt peripheral vascular disease, HBA1c >7%, and preoperative critical state that is defined by the EuroSCORE II as: ventricular tachycardia or ventricular fibrillation or aborted sudden death, preoperative cardiac massage, preoperative ventilation before anesthesia, use of inotropes or IABP, and acute renal failure that defined by anuria or oliguria <10ml/hr. were also excluded. Depending on the technique used to harvest LIMA, patients were allocated to one of the following two groups: Group 1: pedicled LIMA (n=200), and Group 2: skeletonized LIMA (n=100).

Management protocol:

The perioperative protocol for CABG patients at our institutions included a full medical history and physical examination, routine laboratory and imaging studies, coronary angiography study, cessation of antiplatelet medications, and continuation of angiotensin-converting-enzyme inhibitors, beta-blockers, calcium channel blockers, and standardized anesthetic management.

Preoperative hygienic anti-infection measures included: hair removal either with shaving or clipping at night before the operation and skin preparation shower with either povidone-iodine (Betadine) alone or povidone-iodine and alcohol. The shower was recommended at night only or at night and one hour before the operation. The routine antibiotic prophylaxis regimens at our centers included intravenous administration of first or second-generation cephalosporins (within 30-60 minutes before skin incision), as staphylococcal strains are known as a major

causative organism. In patients with β -lactams allergy, vancomycin was administered in a dose of 15mg/kg/dose over 30 minutes.

Pedicled LIMA graft was performed as standard and included fascia, muscles, and internal mammary vein and artery. As in the pedicled technique, in skeletonization, the pleura was brushed off the endothoracic fascia over the IMA, then, a diathermy incision was done in the endothoracic fascia immediately medial to the vascular bundle, and the fascia was reflected to expose the LIMA and the accompanying veins. Using the veins for retraction, the LIMA was detached from the chest wall by applying the diathermy in the intercostal spaces, and the arterial branches were divided in the same way as in the pedicled technique. Following full mobilization, the LIMA was divided distally. Heparin was administered as the dissection of the LIMA was being completed. The LIMA was then divided, and a clip was placed on the artery near the open end, and the distal segment of the artery on the chest wall was ligated with silk sutures.

Excessive diathermy was defined as the liberal use of the electrocautery for dividing the presternal soft tissues instead of meticulous pinpoint hemostasis on the skin and subcutaneous bleeding vessels only or if the power output was set too high producing flame-throwing [7]. Excessive use of bone wax was considered if liberal applying of bone wax to the sternal edges, whether friable/bleeding or not [8]. We applied the traditional figure-of-eight technique with interrupted wires for sternal closure. Robicsek sternal closure technique was used for obese and osteoporotic patients.

The patients received the standardized postoperative care, and they were followed up at outpatient clinics, at intervals of two weeks, six weeks, and three months after surgery. All patients completed a follow-up period of three months after CABG surgery. The evaluation during follow-up included: (1) sternal instability: identified either on physical examination while placing fingers along the sternotomy incision during inspiration, and cough, or reporting sternal clicking by the patient with the same actions; (2)

signs of wound infection: erythema, edema, pain, and wound discharge; (3) temperature; (4) microbiological study when there is a wound discharge; (5) chest CT if SWI was suspected and clinical examination alone cannot confirm the diagnosis. The extent of SWI was classified according to Jone's criteria, which depend strictly on features encountered at the time of sternal exploration, describing three different types of SWIs, encompassing both superficial and deep infections, and specify a physiologically meaningful class; Type 3b, for the patient who is systemically ill from the SWI (Table 1). The protocol of management of mediastinitis at our institutions was primary closure, where surgical revision of the wound with extensive debridement and removal of all devitalized and necrotic tissues, sternal reclosure, with or without mediastinal antibiotic irrigation was done. Sometimes the sternal defect required vascularized muscle flaps (pectoralis major, or rectus abdominis) or omental flaps to obliterate the dead space. Additionally, Vacuum-Assisted Closure (VAC) therapy was either used as a single line of treatment or followed by a second-line procedure as primary closure or flap transposition.

Table 1: The classification system of sternal wound infection modified from Jones et al. criteria [6]

Classification	Depth	Description
Type 1a	Superficial	Skin and subcutaneous
Type 1b	Superficial	Exposure of deep fascia, intact sutures
Type 2a	Deep	Bone exposure, sternum with stable wire
Type 2b	Deep	Bone exposure, sternum with unstable wire
Type 3a	Deep	Necrotic bone/heart exposure, unstable wire
Type 3b	Deep	Type 2 or 3 with septicemia

Study outcomes:

The primary outcome measured was the incidence of SWIs within three months after CABG. The secondary outcome measures included: duration of ventilation, hospital stay, low cardiac output, blood transfusion, arrhythmias, reoperation for bleeding/tamponade, pulmonary

Table 2: Pre- and intra-operative characteristics of the studied patients. Continuous data are presented as mean and SD and categorical data as number and percent.

Variables	Group 1 (n=200)	Group 2 (n=100)	p-value
Age (years)	56.23± 8.7	54.95± 4.54	0.20
Sex (M/F)	171(85.5%)/29(14.5%)	82(82%)/18(18%)	0.43
BMI (kg/m ²)	28.81± 4	29.69± 5.71	0.12
NYHA I/II	149 (74.5%)	78 (78%)	0.50
Diabetes mellitus	101 (50.5%)	44 (44%)	0.28
Current smokers	30 (15%)	21 (21%)	0.31
COPD	5 (2.5%)	4 (4%)	0.60
Ejection fraction	59.72± 7.43	58.4± 7.36	0.14
Euroscore II	1.25± 0.62	1.37± 0.58	0.09
Bypass time (min)	96.36± 35.12	101.14± 30.38	0.24
Cross-clamp time (min)	58.02± 22.43	64.53± 63.14	0.19
Total operative time (min)	190.78± 55	212.77± 75.25	0.004
Excessive bone wax	38 (19%)	1 (1%)	0.0001
Excessive diathermy	29 (14.5%)	7 (7%)	0.06

IMA: Internal thoracic artery. BMI: Body mass index. NYHA: New York Heart Association. COPD: Chronic obstructive pulmonary disease.

complications, neurological complications, and renal complications.

Statistical analysis:

Statistical analysis was performed using the IBM SPSS Statistics for Windows, Version 22 (IBM SPSS Statistics for Windows, IBM Corporation, Armonk, NY, USA). Quantitative data were expressed as mean ± standard deviation, and qualitative data were expressed as number and percentage. Quantitative variables were assessed for normality and compared with the t-test or non-parametric Mann-Whitney test as appropriate.

Chi-square or Fisher's exact test was used to compare qualitative data. A multivariable binary logistic regression model was used to determine the risk factors of DSWI that were significant in the univariable analysis. For all statistical comparisons, a p-value of ≤ 0.05 was considered significant.

Results

Comparison of pre- and intra-operative data between both groups (Table 2) showed non-significant differences in age (56.23±8.7 years vs. 54.95±4.54 years, p= 0.20), male to female ratio

Table 3: Postoperative outcomes in the studied patients. Categorical data are presented as number and percent.

Variables	Pedicle IMA (n=200)	Skeletonized IMA (n=100)	P-value
Sternal wound infection	31 (15.5%)	4 (4%)	0.003
Duration of ventilation (hours)	11.44 ± 8.44	10.57 ± 9.07	0.41
Hospital stay (days)	6.5 ± 4	5.7 ± 3.6	0.09
Low cardiac output	57 (28.5%)	31 (31%)	0.38
Blood transfusion	149 (74.5%)	81 (81%)	0.21
Arrhythmias	6 (3%)	2 (2%)	0.74
Reoperation for bleeding/tamponade	22 (11%)	6 (6%)	0.16
Pulmonary complications:	4 (2%)	2 (2%)	>0.99
Prolonged intubation	3 (1.5%)	1 (1%)	>0.99
Pneumonia	1 (0.5%)	1 (1%)	>0.99
Neurological complications	1 (0.5%)	1 (1%)	0.61
Renal failure	1 (0.5%)	1 (1%)	0.61

IMA: Internal thoracic artery

(85.5%/14.5% vs. 82%/18%, $p= 0.43$), body mass index (BMI); (28.81 ± 4 kg/m² vs. 29.69 ± 5.71 kg/m², $p= 0.12$), NYHA I/II (74.5% vs. 77.8% $p= 0.50$), diabetes mellitus (50.5% vs. 44%, $p= 0.28$), current smokers (15% vs. 21%, $p= 0.31$), chronic obstructive pulmonary disease (COPD) (2.5% vs. 4%, $p= 0.60$), ejection fraction ($59.72\pm 7.43\%$ vs. $58.4\pm 7.36\%$, $p= 0.14$), EuroSCORE II (1.25 ± 0.62 vs. 1.37 ± 0.58 , $p= 0.09$), bypass time (96.36 ± 35.12 min vs. 101.14 ± 30.38 min, $p= 0.24$), cross-clamp time (58.02 ± 22.43 min vs. 64.53 ± 63.14 min, $p= 0.19$), and excessive diathermy (14.5% vs. 7%, $p= 0.06$). There was a significant increase in the total operative time in skeletonized LIMA group (212.77 ± 75.25 min vs. 190.78 ± 55 min, $p= 0.004$). Additionally, there was a significant increase in the frequency of excessive intraoperative use of bone wax in pedicled LIMA group (19% vs. 1%, $p< 0.001$).

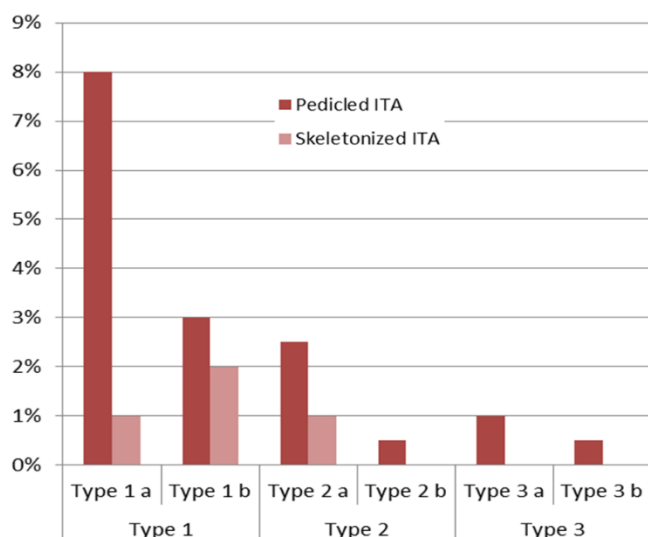


Figure 1: Distribution of different types of sternal wound infection between pedicled and skeletonized internal mammary artery

The group of skeletonized LIMA showed a significantly lower incidence of SWI than that in pedicled IMA group (4% vs. 15.5%, $p= 0.003$) (Table 3). Moreover, the skeletonized LIMA group showed a lower frequency of deep SWI (Types 2 and 3 Jones classification) than pedicled LIMA (Figure 1). Still, this difference did not reach the statistical significance (1% vs. 4.5%, $p= 0.11$). There were no significant differences between both groups regarding the postoperative duration of ventilation, hospital stay, low cardiac output, blood transfusion, arrhythmias, reoperation for

bleeding/tamponade, pulmonary complications (prolonged intubation and pneumonia), neurological complications, and renal failure (Table 3).

On multivariable analysis (Table 4), the risk factors for SWI in CABG patients who had pedicled LIMA were obesity (OR: 13.06, 95%CI: 3.98-42.89), diabetes mellitus (OR: 10.51, 95%CI: 2.35-46.84), and excessive diathermy (OR: 12.62, 95%CI: 3.93-40.54).

Table 4: Multivariable logistic regression analysis of risk factors for sternal wound infection in patients with pedicled internal mammary artery

Variables	Beta	P-value	OR	95% CI for OR	
				Lower	Upper
Obesity	2.57	<0.01	13.06	3.98	42.89
DM	2.35	<0.01	10.51	2.35	46.84
Excessive diathermy	2.53	<0.01	12.62	3.93	40.54

DM: Diabetes mellitus. OR (95% CI): Odds ratio (95% Confidence Interval).

Discussion

Sternal wound infection is one of the most severe complications following CABG, because it can lead to a significant burden on health care budgets [9]. In the present study, the overall incidence of SWI after CABG was 11.7% ($n= 35$). The incidence of superficial SWI (Jones types 1) was about 8% ($n= 25$), and these cases were treated with antibiotics and wound care, while deep SWI (Jones types 2 and 3) had an incidence approximates 3% ($n= 10$), and all of these cases required surgical debridement and rewiring. These findings are within the reported ranges of superficial and deep SWIs in the literature. The reported incidences of superficial SWI ranged from 0.5% to 12% [10-12]. The incidence of deep SWI, despite advances in prevention, remains high and ranges between 0.5% and 6.8% [9, 13, 14, 15].

The decision to skeletonize the LIMA during CABG surgery should be made according to the surgeons' preference. However, there are instances when skeletonizing the LIMA is preferable to a pedicled graft in terms of longer length, increased blood flow, less spasm, and lower incidences of SWI [16]. In the present study,

in comparison to pedicled LMA, skeletonized LIMA results in significantly lower incidence of SWI (4% vs 15.5%, $P = 0.003$) and lower incidence of deep SWI (1% vs 4.5%, $P = 0.11$). Additionally, skeletonization was associated with relatively shorter hospital stay (5.7 ± 3.6 vs 6.5 ± 4 days, $P = 0.09$) and shorter duration of ventilation (10.57 ± 9.07 vs 11.44 ± 8.44 hours, $P = 0.41$) despite not significant.

These findings are consistent with other studies, which examined the effects of LIMA grafting on postoperative complications using the skeletonized versus pedicled method. Sa and coworkers conducted a meta-analysis of 22 studies involving 4817 patients (2424 skeletonized; 2393 pedicled) and concluded that skeletonized IMA could reduce the incidence of postoperative SWI in comparison with pedicled IMA [17]. Fouquet and coworkers reported that despite longer operative times, skeletonization led to fewer wound infections, reduced chest pain, allowed a shorter hospital stay, and preserved pulmonary functions [18]. The lower incidence of SWI with skeletonized LIMA can be explained by the studies which investigated the effects of IMA harvesting on sternal blood flow. The pedicled technique is the standard way to harvest LIMA, but it can lead to critical devascularization of the sternum. Since sternal ischemia is one of the major factors in the pathophysiology of sternal wound complications, skeletonization was proposed as an alternative technique that would preserve sternal vascularity [19].

However, Nishi and coworkers carried out a prospective cohort study of 46 patients using a novel laser Doppler flowmeter to evaluate changes in sternum microcirculation prior to and after LIMA harvesting. They found no difference in sternum microcirculation in the skeletonized group or the pedicled group, suggesting that skeletonization is not advantageous for maintaining sternal microcirculation [20]. This controversy may imply that factors, other than reduced blood flow, may be responsible for the development of sternal infections following LIMA harvesting, irrespective of which harvesting technique is used. One of these factors is how the sternum is closed [16].

In the present study, the risk factors for SWI in CABG patients with pedicled LIMA were obesity, diabetes mellitus, and excessive diathermy. The skeletonization harvest technique had been reported to reduce the incidence of deep SWI, particularly in diabetics and obese patients, because of the better preservation of collateral sternal blood flow and internal thoracic veins [21]. However, some cardiothoracic surgeons are reluctant to apply this technique as it can easily lead to graft conduit damage [3].

Despite the significant difference in the frequency of excessive intraoperative use of bone wax between both groups, the multivariate analysis of the independent factors of SWI in the pedicled group did not show that excessive use of bone wax was a significant predictor of SWI.

Study limitations

The study has several limitations. We included patients who had unilateral IMA only; thus, the findings should not be considered for cases with bilateral IMA. The choice of the pedicled or skeletonized technique was related to the surgeon's preference without the randomization of the patients, which could have led to selection bias. Another limitation was the absence of a postoperative patency study. However, this study has some strength, being prospective and multicenter study, which avoids the bias of retrospective studies and allows variation in techniques and characteristics of the patients. Although the cases were non-randomized, there was no difference in the baseline data between both groups. Confounding might be controlled with exclusion criteria.

Conclusion

Skeletonization of LIMA during CABG was associated with lower incidences of deep and superficial sternal infections in comparison with the pedicled LIMA. Other risk factors may influence the unfavorable impact of this technique on the sternal wound, including obesity, diabetes, and the use of excessive diathermy for hemostasis. Skeletonization may be preferred for patients with a higher chance for SWI, especially obese and diabetic patients.

Conflict of interest: Authors declare no conflict of interest.

References

- Gaughan J, Kobel C. [Coronary artery bypass grafts and diagnosis-related groups: patient classification and hospital reimbursement in 10 European countries](#). *Health Econ Rev*. 2014; 4: 4
- Bakaeen F. [CABG: A continuing evolution](#). *Cleve Clin J Med*. 2017; 84 (12 Suppl 4): e15-e19.
- Saso S, James D, Vecht JA, et al. [Effect of skeletonization of the internal thoracic artery for coronary revascularization on the incidence of sternal wound infection](#). *Ann Thorac Surg*. 2010; 89: 661-70.
- Mannacio V, Di Tommaso L, De Amicis V, Stassano P, Vosa C. [Randomized flow capacity comparison of skeletonized and pedicled left internal mammary artery](#). *Ann Thorac Surg*. 2011; 91 (1): 24-30.
- Hu X, Zhao Q. [Skeletonized internal thoracic artery harvest improves prognosis in high-risk population after coronary artery bypass surgery for good quality grafts](#). *Ann Thorac Surg*. 2011; 92 (1): 48-58.
- Raja SG, Dreyfus GD. [Internal thoracic artery: to skeletonize or not to skeletonize?](#) *Ann Thorac Surg*. 2005; 79 (5): 1805-11.
- Nishida H, Grooters RK, Soltanzadeh H, Thieman KC, Schneider RF, Kim WP. [Discriminate use of electrocautery on the median sternotomy incision. A 0.16% wound infection rate](#). *J Thorac Cardiovasc Surg*. 1991; 101 (3): 488-94.
- Alhan C, Artürk C, Senay S, et al. [Use of bone wax is related to increased postoperative sternal dehiscence](#). *Kardiochir Torakochirurgia Pol*. 2014;11(4):385-90.
- Cotogni P, Barbero C, Rinaldi M. [Deep sternal wound infection after cardiac surgery: Evidences and controversies](#). *World J Crit Care Med*. 2015; 4 (4): 265-73.
- Singh K, Anderson E, Harper JG. [Overview and management of sternal wound infection](#). *Semin Plast Surg*. 2011; 25 (1): 25-33.
- Lindblom RP, Lytsy B, Sandström C, et al. [Outcomes following the implementation of a quality control campaign to decrease sternal wound infections after coronary artery bypass grafting](#). *BMC Cardiovasc Disord*. 2015; 15: 154.
- Lazar HL, Salm TV, Engelman R, Orgill D, Gordon S. [Prevention and management of sternal wound infections](#). *J Thorac Cardiovasc Surg*. 2016; 152 (4): 962-72.
- Lemaigen A, Birgand G, Ghodhbane W, et al. [Sternal wound infection after cardiac surgery: incidence and risk factors according to clinical presentation](#). *Clin Microbiol Infect*. 2015; 21 (7): 674.e11-8
- Egito JG, Abboud CS, Oliveira AP, et al. [Clinical evolution of mediastinitis in patients undergoing adjuvant hyperbaric oxygen therapy after coronary artery bypass surgery](#). *Einstein (Sao Paulo)*. 2013; 11(3):345-9.
- Litwinowicz R, Bryndza M, Chrapusta A, Kobielska E, Kapelak B, Grudzień G. [Hyperbaric oxygen therapy as additional treatment in deep sternal wound infections – a single center’s experience](#). *Kardiochir Torakochir Pol*. 2016; 13: 198–202.
- Lazar HL. [The risk of mediastinitis and deep sternal wound infections with single and bilateral, pedicled, and skeletonized internal thoracic arteries](#). *Ann Cardiothorac Surg*. 2018; 7(5):663-672.
- Sa MP, Ferraz PE, Escobar RR, et al. [Skeletonized versus pedicled internal thoracic artery and risk of sternal wound infection after coronary bypass surgery: meta-analysis and meta-regression of 4817 patients](#). *Interact Cardiovasc Thorac Surg*. 2013; 16 (6): 849-57.
- Fouquet O, Tariel F, Deslulauze P, Mével G. [Does a skeletonized internal thoracic artery give fewer postoperative complications than a pedicled artery for patients undergoing coronary artery bypass grafting?](#) *Interact Cardiovasc Thorac Surg*. 2015; 20 (5): 663-8
- De Paulis R, de Notaris S, Scaffa R, et al. [The effect of bilateral internal thoracic artery harvesting on superficial and deep sternal infection: the role of skeletonization](#). *J Thorac Cardiovasc Surg* 2005; 129: 536–43.
- Nishi H, Mitsuno M, Tanaka H, Ryomoto M, Fukui S, Miyamoto Y. [Decreasing sternum microcirculation after harvesting the internal thoracic artery](#). *Eur J Cardiothorac Surg*. 2011; 40: 240–4.

21. Peterson MD, Borger MA, Rao V, Peniston CM, Feindel CM. [Skeletonization of bilateral internal thoracic artery grafts lowers the risk of](#)

[sternal infection in patients with diabetes.](#) J Thorac Cardiovasc Surg 2003; 126: 1314–9.